



Original Article

The role of transforaminal nerve block in the treatment of lumbar disc herniation and spinal canal stenosis

Yusuf Sharaf, MUDR¹, Baha Taha², Zahra R. Alzaimoor, MD¹, Yakub K. Sayyad, BHMS³¹Alsharaf Orthopedic and Spine Center, Manama, Bahrain, ²Department of Anaesthesiology, Campbellton Regional Hospital, Campbellton, NB, Canada,³Department of Clinical Research, Shifa Clinic, Pune, Maharashtra, India.

*Corresponding author:

Yusuf Sharaf, MUDR,
Alsharaf Orthopedic and Spine
Center, Manama, Bahrain.

dr.yusif.sharaf@gmail.com

Received: 12 November 2022

Accepted: 14 January 2023

Epub Ahead of Print: 03 February 2023

Published: 07 February 2023

DOI

10.25259/JMSR_139_2022

Quick Response Code:



ABSTRACT

Objectives: This study aimed to evaluate patients undergoing transforaminal nerve block treatment in lumbar disc herniation (LDH) and spinal canal stenosis.**Methods:** It is an observational descriptive cross-sectional study at a single tertiary care hospital. It is based on a review of electronic medical records of patients suffering from lower back pain from either LDH or spinal canal stenosis and who underwent transforaminal nerve blocks between January 2019 and December 2021.**Results:** A total of 440 patients were included in this study. Study findings reported that the etiology behind the treatment was mostly due to spinal canal stenosis with 223 cases (50.7%), followed by disc bulge with 208 cases (47.3%), two cases had both diagnoses, and the others had different etiologies such as degenerative disease with scoliosis, micro decompression. The visual analog scale pain score was highest on the pre-injection time point (7.1 ± 1.1) and decreased significantly with time after the injection to reach 2.7 ± 1.04 after 6 months. Similarly, the Oswestry Disability Index was high during pre-injection (64.9 ± 7.5) and decreased significantly to 19.3 ± 16.2 after 1-day post-injection and 13.2 ± 3.8 after 6 months.**Conclusion:** This study proves that transforaminal nerve block is an alternative treatment with proven efficacy and safety with quick pain relief in these patients, especially in the early phase, with immediate benefit.**Keywords:** Epidural analgesia, Epidural injection, Low back pain, Minimally invasive surgery, Spinal puncture

INTRODUCTION

Disc herniation is widely known as the leading cause of lumbar and leg pain restraining one's mobility and, far worse, unable to care for themselves and perform the routine activities of daily living.^[1] Moreover, lumbar disc herniation (LDH) and lumbar central spinal stenosis (LCSS) are two main factors responsible for lower back pain in older people, where LCSS can also be due to LDH.^[2,3] Most LDH develop on the L4-5 or L5-S1 levels.^[4,5] In addition, younger individuals are at higher risk of recurrent LDH.^[6] On the other hand, lumbar canal stenosis (LCS) is described as progressive spinal canal narrowing with nerve root impingement resulting in degeneration, which is most commonly reported in the older population. Furthermore, patients with LCS often suffer from intermittent claudication, which is the main diagnostic feature.^[7] Pain resulting from

How to cite this article: Sharaf Y, Taha B, Alzaimoor ZR, Sayyad YK. The role of transforaminal nerve block in the treatment of lumbar disc herniation and spinal canal stenosis. J Musculoskelet Surg Res 2023;7:34-9.

these conditions is usually the trigger to seeking medical care.

Given that there is no cauda equina syndrome nor progressive neurologic deficit, an elective lumbar disc surgery can be performed when the pain persists for a minimum of 6 weeks following non-operative treatments.^[8] However, even with a success rate as high as 92–98%, studies revealed that there is no statistically significant difference between operative and non-operative treatment outcomes in the long run.^[8] Therefore, longitudinal evaluation on 7–20 years of follow-up showed that satisfactory findings were only reported in 64% of study patients.^[9] Nevertheless, the previous evidence reported that it is not always necessary to perform surgery in the cases of LCSS or LDH.^[10]

Many studies proved the efficacy of transforaminal nerve block with rapid pain relief as a treatment for disc herniation. It became the main treatment administered for lumbar and leg pain due to LDH.^[11-14] Lidocaine is mostly used as a nerve block with its rapid onset of action, efficacy, and duration, which can be administered alone or combined with steroids for these conditions' treatment. However, there are still contrasting findings on which treatment strategy is sufficient.^[2] Nevertheless, it also has some drawbacks, including the dependence on the operator's expertise when injected blindly and accidental injuries to neighboring nerves or vessels. Therefore, it is important to evaluate its effectiveness and drawbacks.^[1] To better illustrate this point, this study aimed to assess patients undergoing transforaminal nerve block for LDH and LCS management.

MATERIALS AND METHODS

Study design and participants

This is an observational cross-sectional study at a single tertiary care hospital, Al-Sharaf Orthopedic and Spine Specialist Center, Kingdom of Bahrain. It is based on a review of electronic medical records of patients suffering from lower back pain from either LDH or LCS and who underwent transforaminal nerve blocks between January 2019 and December 2021. All adults aged more than 18 years and with a magnetic resonance imaging report confirming the diagnosis were included in the study. Patients with the previous lumbar surgery or who have a contraindication for the treatment used were excluded from the study.

Procedure

The procedure was done in a sterile field, where local anesthesia was used during the procedure. A sterile eye sheet drape was placed on the site. The patients were kept in a prone position. The transforaminal nerve block technique required (a) 1% lidocaine injection, 5 mL, for subcutaneous

anesthesia for the needle infiltration site, (b) depo Medrol injection, 80 mg, and (c) 1% marcain, 20 mL at the nerve root.

Fluoroscopic guidance was used to identify the site and then a subcutaneous needle of lidocaine 1% was inserted. The nerve block needle for the procedure was a 20G × 3.50-inch × 0–90 × 90 mm spinal needle.

The vertical lower center of the pedicle presented over the passing nerve roots was considered the main target. After finding the level and checking the absence of both blood and cerebrospinal fluid, the nerve block injection was administered inside the epidural space medial to the pedicle. After the insertion of the needle, a minute was given to see if there was blood in the tubing. After confirming the absence of both blood and cerebrospinal fluid, a contrast medium was injected (OMNIOPAQUE). Using fluoroscopy, observations were made of spreading the contrast medium inside the epidural space medial to the pedicle. Fluoroscopic images were recorded on a real-time basis to look for intravascular spreading. Five millimeters of 1% lidocaine were administered subcutaneously to the needle infiltration site. Then Depo-Medrol and marcain were injected by targeting the affected nerve root causing the pain. For each level, the protocol was the same. After the injection, patients were placed in a supine position. The patient's general condition was checked every 15 min, post-operative instructions were given, and they were discharged with follow-up appointments.

Statistical analysis

The Statistical Package for the Social Sciences (SPSS) software (SPSS version 24.0) was used for all statistical analysis. Descriptive results are presented as mean ± standard deviation for all quantitative variables (such as age), whereas number (percentage) is reported for all categorical variables (such as gender). In addition, a repeated measures analysis of variance (ANOVA) with a Greenhouse-Geisser correction was used to compare the pain score and Oswestry disability index at different time points.

RESULTS

A total of 440 patients presented to the hospital suffering from the lower back pain from either LDH or LCS and underwent transforaminal nerve blocks during the study period. Their clinical and demographic data are presented in [Table 1]. The participants were 18–96 years old, with a mean age of 54.2 ± 14.9 years. Women were slightly predominant compared to men (54.3% vs. 45.7%). The number of patients who underwent transforaminal nerve block was almost similar during the three years, with the highest percentage in 2021 (39.5%). The causes of seeking

Table 1: Patients characteristics (n=440).

		Number	Percentage
Age	54.2±14.9 (Min: 18 Max: 96)		
Gender			
Male		201	45.7
Female		239	54.3
Year of treatment			
2019		124	28.2
2020		142	32.3
2021		174	39.5
Reason			
Degenerative disease with scoliosis		1	0.2
Disc bulge		208	47.3
Disc protrusion		1	0.2
Extraforaminal disc		1	0.2
Spinal canal stenosis		223	50.7
Both stenosis and disc bulge		2	0.5
Spondylolisthesis		3	0.7
Pain VAS score			
Pre-injection	7.1±1.1 (Min: 5 and Max: 10)		
One-day post-injection	3.4±1.7 (Min: 1 and Max: 10)		
Three months post-injection	3.3±1.01 (Min: 1 and Max: 5)		
Six months post-injection	2.7±1.04 (Min: 0 and Max: 5)		
Oswestry disability index			
Pre-injection	64.9±7.5 (Min: 5 and Max: 80)		
One-day post-injection	19.3±16.2 (Min: 1 and Max: 80)		
Three months post-injection	13.3±3.4 (Min: 1 and Max: 22)		
Six months post-injection	13.2±3.8 (Min: 2 and Max: 23)		
Results			
Improved		393	89.3
Microdecompression		25	5.7
Microdiscectomy		22	5

VAS: Visual analog scale

Table 2: Distribution of sites.

	Frequency	Percentage
TNB L2-L5	3	0.7
TNB L3-L4	7	1.6
TNB L3-L4, L4-L5, L5-S1	5	1.1
TNB L3-L4 and L4-L5	28	6.4
TNB L3-L5	3	0.7
TNB L3-S1	4	0.9
TNB L4-L5	171	38.9
TNB L4-L5 and L5-S1	124	28.2
TNB L5-S1	77	17.5
Others	18	4.1

TNB: Transforaminal nerve block

treatment mainly were due to LCS (50.7%) followed by LDH (47.3%), 2 cases had both diagnoses, and the others had different etiologies such as degenerative disease with scoliosis and micro-decompression. [Table 2] shows the distribution of the sites with the highest proportion in the L4-L5 level (38.9%), followed by L4-L5 and L5-S1 levels

(28.2%) and L5-S1 level (17.5%). The visual analog scale (VAS) pain score was highest on the pre-injection time point (7.1 ± 1.1) and decreased after the injection to reach 2.7 ± 1.04 after 6 months. Similarly, the Oswestry Disability Index was high during pre-injection (64.9 ± 7.5) and decreased to 19.3 ± 16.2 only after 1-day post-injection and 13.2 ± 3.8 after 6 months. A total of 393 patients (89.3%) who underwent transforaminal nerve block had significant improvement, while 5.7% had micro-decompression and 5% had microdiscectomy.

Repeated measures ANOVA showed that the mean VAS pain score was significantly different between time points ($F [2.434, 951.509] = 2054.537, P < 0.0001$). Furthermore, Bonferroni *post hoc* showed that the VAS pain score was statistically significantly decreased from pre-intervention to 1 day, 3- and 6-month post-intervention, and even between all the post-injection periods. As for the Oswestry disability index over time, the mean also was significantly different between time points ($F [2.007, 780.713] = 9612.77, P < 0.0001$), yet no difference in the *post hoc* analysis

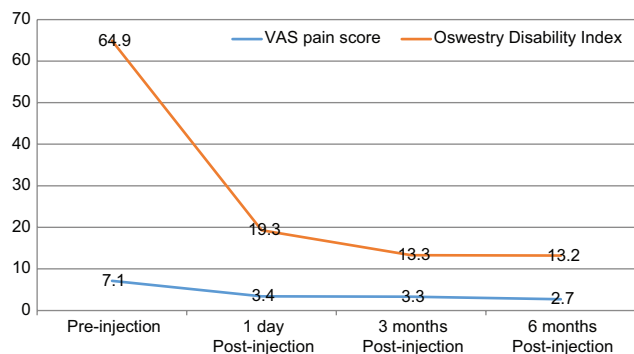


Figure 1: Visual analog scale pain score and Oswestry disability index over time ($P < 0.0001$).

between 3 months post-intervention and 6 months post-intervention (0.049 [95% CI, -0.139–0.237] mg/L, $P = 1$) [Figure 1].

DISCUSSION

In patients suffering from lower back and leg pain, the etiology is usually due to LCS, intervertebral disc protrusion/extrusion, and intervertebral disc degeneration.^[15] Pain management is essential in the treatment of these patients until disease resolution. Transforaminal nerve blocks as a minimally invasive approach were proven in this study to be an effective treatment for these patients with improved pain in the short term. The transforaminal epidural injection was reported to be a safe and effective treatment module as a non-surgical treatment for LCS and LDH.^[16] Many mechanisms have been described, such as that the corticosteroids stop the arachidonic acid production resulting in the inhibition of the pain-generating pathway or directly relieving central pain sensitization. Another possibility is that the nerve roots stretch due to injections in the epidural space, causing the lysis of neural adhesions, with more pain relief. Alternative hypotheses reported cell membrane stabilization, enhancement of neuronal blood flow and washing out different inflammatory mediators such as interleukin-1 and tumor necrosis factor.^[17]

Findings suggested a positive effect, as almost all patients suffering from pain secondary to LDH and LCS and underwent transforaminal nerve block had significant improvement in the short-term phase (less than a day) without any reported complications. Literature reported three different modalities of epidural steroid injections: Caudal, requiring a greater volume of medication, and interlaminar, which delivers near the site desired. The third modality is transforaminal, which is the most preferred modality because it is target-specific and requires a smaller amount of administered treatment to act on the pathology.^[18] In addition, no additional complications were

recorded in our sample. The previous evidence reported an association between corticosteroid use and possible complications, including higher blood glucose levels in diabetic cases, yet reported a higher absorption rate of extruded hernias.^[19] This was aligned with the previous literature where the epidural block has been proven effective and used in treating acute pain, yet, its long-term effect is still controversial.^[20]

A previous Chinese study compared patients receiving either lumbar transforaminal epidural block (LTEB) or simple, comprehensive treatment (physiotherapy, massage, and traction) to assess its efficacy in treating low back pain. Findings showed that the proportion of women was higher than men in both groups (60.6% in the LTEB arm and 57.8% in the controls), which aligns with our results.^[21]

Present findings reported the etiology behind the treatment was mostly due to LCS (50.7%) followed by disc bulge (47.3%) were sites with the highest proportion in the L4-L5 level (38.9%), followed by L4-L5 and L5-S1 levels (28.2%) and L5-S1 level (17.5%). L4-5 decompression is necessarily combined with L5-S1 foraminal enlargement in L5 radiculopathy caused by the double crush at the central L4-5 and foraminal L5-S1 levels.^[22] The L5-S1 foraminal stenosis, also known as lumbosacral foraminal, presents distinct anatomical and functional characteristics given to the lumbosacral junction being more prone to major loading from the trunk. Given its pathology, the risk of narrowing of the canals in the spine is mainly in the lower lumbar segments. Mostly involving the described levels in our findings, such as the L5 nerve root (75%) in addition to the L4 root (15%).^[23] However, previous evidence highlighted that on the level of lumbosacral junction, the cause of L5 nerve root compression is usually extraforaminal LDH, accounting for 1–12% of total LDH, or stenosis caused by reduced L5-S1 disc height.^[24]

During the reduced pain period, the patients should gradually increase their activities and start simple exercises for muscle toning and back strengthening. After the procedure, many precautions must be respected: (a) It is important that someone else drive the patient home, (b) walking is allowed right after, and avoiding lifting heavy objects, bending the back, sitting for a long time or on the floor, and (c) the patient can start physiotherapy after 2 days from the procedure.^[25]

Our descriptive study has some limitations, such as the cross-sectional design, which is less potent than a cohort study. In addition, the information has been gathered from a single center, so the results cannot be generalizable.

CONCLUSION

This study showed that transforaminal nerve blocks were found effective as a temporary alternative treatment with

proven efficacy in quick pain relief. Most benefits are described in the immediate or early phase after the injection.

AUTHORS' CONTRIBUTIONS

YS confirms responsibility for the study conception and design, data collection, analysis and interpretation of results, and manuscript preparation. YKS and ZR did all statistical analysis and interpretation, writing of the results. BT contributed to the final writing of the research paper. All authors have critically reviewed and approved the final draft and are responsible for the manuscript's content and similarity index.

ETHICAL APPROVAL

Ethical approval was obtained from Al-Sharaf Orthopedic and Spine Specialist Center with the following approval number ALSOSC/1796, dated 25 December 2018.

DECLARATION OF PATIENT CONSENT

The authors certify that they have obtained all appropriate patients consent forms. In the form, the patients have given their consent for their images and other clinical information to be reported in the journal. The patients understand that their names and initials will not be published and due efforts will be made to conceal their identity, but anonymity cannot be guaranteed.

FINANCIAL SUPPORT AND SPONSORSHIP

This study did not receive any specific grant from funding agencies in the public, commercial, or not-for-profit sectors.

CONFLICTS OF INTEREST

There are no conflicting relationships or activities.

REFERENCES

- Guang-Hui L, Guang-Yu Z, Yu-Zhang L, Yong-Tao Z, Shi-Min Z, Jiao J. Value of ultrasound-guided transforaminal nerve block in the treatment of lumbar disc herniation. *J Int Med Res* 2020;48.
- Zhao W, Wang Y, Wu J, Gao X, Wei Q, Lai X, *et al.* Long-term outcomes of epidurals with lidocaine with or without steroids for lumbar disc herniation and spinal stenosis: A meta-analysis. *Pain Physician* 2020;23:365-74.
- Otani K, Kikuchi S, Yabuki S, Igarashi T, Nikaido T, Watanabe K, *et al.* Lumbar spinal stenosis has a negative impact on quality of life compared with other comorbidities: An epidemiological cross-sectional study of 1862 community-dwelling individuals. *ScientificWorldJournal* 2013;2013:590652.
- Atlas SJ, Deyo RA, Keller RB, Chapin AM, Patrick DL, Long JM, *et al.* The maine lumbar spine study, Part II. 1-year outcomes of surgical and nonsurgical management of sciatica. *Spine (Phila Pa 1976)* 1996;21:1777-86.
- Weinstein JN, Tosteson TD, Lurie JD, Tosteson AN, Hanscom B, Skinner JS, *et al.* Surgical vs nonoperative treatment for lumbar disk herniation: The spine patient outcomes research trial (SPORT): A randomized trial. *JAMA* 2006;296:2451-9.
- Lagerbäck T, Möller H, Gerdhem P. Lumbar disc herniation surgery in adolescents and young adults: A long-term outcome comparison. *Bone Joint J* 2019;101-B:1534-41.
- Kong L, Bai J, Zhang B, Shen Y, Tian D. Predictive factors of symptomatic lumbar canal stenosis in patients after surgery for cervical spondylotic myelopathy. *Ther Clin Risk Manag* 2018;14:483-8.
- Rogerson A, Aidlen J, Jenis LG. Persistent radiculopathy after surgical treatment for lumbar disc herniation: Causes and treatment options. *Int Orthop* 2019;43:969-73.
- Loupasis GA, Stamos K, Katonis PG, Sapkas G, Korres DS, Hartofilakidis G. Seven-to 20-year outcome of lumbar discectomy. *Spine (Phila Pa 1976)* 1999;24:2313-7.
- Udeh BL, Costandi S, Dalton JE, Ghosh R, Yousef H, Mekhail N. The 2-year cost-effectiveness of 3 options to treat lumbar spinal stenosis patients. *Pain Pract* 2015;15:107-16.
- Beynon R, Elwenspoek MM, Sheppard A, Higgins JN, Kolias AG, Laing RJ, *et al.* The utility of diagnostic selective nerve root blocks in the management of patients with lumbar radiculopathy: A systematic review. *BMJ Open* 2019;9:e025790.
- Jang JH, Lee WY, Kim J, Cho KR, Nam SH, Park Y. Ultrasound-guided selective nerve root block versus fluoroscopy-guided interlaminar epidural block versus fluoroscopy-guided transforaminal epidural block for the treatment of radicular pain in the lower cervical spine: A retrospective comparative study. *Pain Res Manag* 2020;2020:9103421.
- Lee JW, Lee E, Lee GY, Kang Y, Ahn JM, Kang HS. Epidural steroid injection-related events requiring hospitalisation or emergency room visits among 52,935 procedures performed at a single centre. *Eur Radiol* 2018;28:418-27.
- Zhang X, Shi H, Zhou J, Xu Y, Pu S, Lv Y, *et al.* The effectiveness of ultrasound-guided cervical transforaminal epidural steroid injections in cervical radiculopathy: A prospective pilot study. *J Pain Res* 2018;12:171-7.
- Emami SA, Sanatkar M, Espahbodi E, Pestehei SK. Ultrasound and nerve stimulator guidance lumbar transforaminal epidural block for the treatment of patients with lumbosacral radicular pain. *Sci Rep* 2022;12:5954.
- Yuce I, Kahyaoglu O, Ataseven M, Cavusoglu H, Aydin Y. Diagnosis and treatment of transforaminal epidural steroid injection in lumbar spinal stenosis. *Sisli Etfal Hastan Tip Bul* 2020;54:327-32.
- Viswanathan VK, Kanna RM, Farhadi HF. Role of transforaminal epidural injections or selective nerve root blocks in the management of lumbar radicular Syndrome-A narrative, evidence-based review. *J Clin Orthop Trauma* 2020;11:802-9.
- Manchikanti L, Benyamin RM, Falco FJ, Kaye AD, Hirsch JA. Do epidural injections provide short-and long-term relief for lumbar disc herniation? A systematic review. *Clin Orthop Relat Res* 2015;473:1940-56.
- Vialle EN, Ueda WK, Vialle LR. Results of treatment of acute

- lumbar disc herniation with transforaminal nerve root block. *Coluna Columna* 2016;15:222-5.
20. Chae JS, Kim W, Choi SH. Effects of local anesthetics with or without steroids in high-volume transforaminal epidural blocks for lumbar disc herniation: A randomized, double-blind, controlled trial. *J Korean Med Sci* 2022;37:e137.
 21. Yubao H, Chen L, Xu Z, Wang J, Liu B. Lumbar transforaminal epidural block for treatment of low back pain with radicular pain. *Nan Fang Yi Ke Da Xue Xue Bao* 2020;40:1804-9.
 22. Orita S, Inage K, Eguchi Y, Kubota G, Aoki Y, Nakamura J, *et al.* Lumbar foraminal stenosis, the hidden stenosis including at L5/S1. *Eur J Orthop Surg Traumatol* 2016;26:685-93.
 23. Jenis LG, An HS. Spine update. Lumbar foraminal stenosis. *Spine (Phila Pa 1976)* 2000;25:389-94.
 24. Jang JS, An SH, Lee SH. Transforaminal percutaneous endoscopic discectomy in the treatment of foraminal and extraforaminal lumbar disc herniations. *J Spinal Disord Tech* 2006;19:338-43.
 25. Cervical Nerve Root Block/Transforaminal Epidural Steroid Injection. Hull University Teaching Hospitals NHS Trust 2020. Available from: <https://www.hey.nhs.uk/patient-leaflet/cervical-nerve-root-block-transforaminal-epidural-steroid-injection> [Last accessed on 2022 Jul 24].