

Original Article

Is reconstructing anterior sternoclavicular joint dislocation by a high-strength tape suture a good choice?

Mohamed A. A. Ibrahim, MD.¹, Elsherbiny A. Elsherbiny, MD.¹, Gamal A. Farag, MD.², Samir A. Nematallah, MD.¹

¹Department of Orthopedic, Al-Azhar University Hospital, Cairo, Egypt, ²Department of Cardio Thoracic surgery, Al-Azhar University, Damietta, Egypt.

*Corresponding author:

Mohamed A. A. Ibrahim,
Department of Orthopedic,
Al-Azhar University Hospital,
Faculty of Medicine, Al-Azhar
University, Cairo, Egypt.

mohamedadel@azhar.edu.eg

Received: 07 March 2023
Accepted: 06 April 2023
Epub Ahead of Print: 24 April 2023
Published: 06 May 2023

DOI

10.25259/JMSR_47_2023

Quick Response Code:



ABSTRACT

Objectives: Sternoclavicular joint (SCJ) dislocation is uncommon but dangerous. Redislocation frequently occurs after manual reduction due to the torn ligaments of the joint with a high-energy injury, which is often the case. Reconstruction of the SCJ is recommended to avoid poor efficacy of conservative treatment and decreasing quality of life in the patient due to progressive pain limiting the movement of the shoulder girdle. Our study aimed to evaluate the efficacy, safety, and patient satisfaction using a high-strength non-absorbable tape suture to reconstruct the anterior SCJ dislocation.

Methods: This study included ten patients (Nine males and one female) who presented with acute anterior dislocation of the SCJ (six on the right and four on the left side). Our patients' average age was 40.1 years (18–52 years), with 12 months on average follow-up (9–18 months). Four patients had isolated anterior SCJ dislocation, while the others had associated injuries.

Results: All patients had excellent functional and satisfactory outcomes and returned to the pre-injury activity level. No intraoperative or major post-operative complications were recorded, and no injuries to near structures or wound problems were noted. The mean improvement of physical function measured by the American shoulder and elbow score was 24.59, which increased from 68.11 ± 3.72 preoperatively to 92.70 ± 3.54 postoperatively.

Conclusion: The technique of open reconstruction of anterior SCJ dislocation using high-strength non-absorbable tape sutures is recommended because it gave us excellent results regarding the safety, functional outcome, patient satisfaction, and avoidance of other surgical site morbidities.

Keywords: Anterior, Dislocation, Non-absorbable tape, Reconstruction, Sternoclavicular joint

INTRODUCTION

Dislocations and fractures of the sternoclavicular joint (SCJ) are infrequent but potentially harmful. In fact, many reports have indicated that about 1% of all severe shoulder injuries are SCJ injuries.^[1]

The SCJ is a genuine diarthrodial joint between the medial clavicle and the clavicular notch of the sternum. A flat and circular fibrocartilaginous structure called the intra-articular disc is connected inferiorly to the first rib costocartilaginous junction and superiorly to the superoposterior part of the clavicular articular surface. The intra-articular disc is fully developed in most people,

How to cite this article: Ibrahim MA, Elsherbiny EA, Farag GA, Nematallah SA. Is reconstructing anterior sternoclavicular joint dislocation by a high-strength tape suture a good choice? J Musculoskelet Surg Res, 2023;7:84-90.

unlike its counterpart in the acromioclavicular joint. Large SCJ ligaments support the thicker anterior and posterior SCJ capsules on either side.^[2-4]

The SCJ's proximity to mediastinal organs such as the esophagus, trachea, brachial plexus, aorta, common carotid arteries, and brachiocephalic veins is more crucial. Having reservations about these structures can affect orthopedic decision-making.^[5]

Often, a patient with SCJ dislocation presents with high-energy trauma (Falls from heights, road traffic accidents, and sports injuries). Trauma to the ipsilateral shoulder, either direct or indirect, may result in SCJ injuries.^[6]

Patients with anterior SCJ displacement typically experience pain restricted to the affected joint, as well as soreness, ecchymosis, and a prominent bony protrusion of the clavicular head. Shoulder motion results in pain and/or an unstable feeling. There is typically no corresponding neurovascular impairment.^[6]

Treatment options can often be categorized based on acuity and displacement direction. The ideal course of treatment for acute anterior SCJ fracture dislocations is hotly debated.^[1]

Particularly in the case of workers or overhead sports, the patient's demands are a significant factor in the treatment and decision-making process. The most recent research on the pathoanatomy, natural history, and potential outcomes of SCJ injuries revealed that surgery could restore normal shoulder girdle morphology and mechanics and enhance functional results even though many of these injuries were treated nonoperatively.^[1]

The surgical management of anterior SCJ dislocation has been documented using several approaches.^[7-10] The figure-of-eight design is the most effective method for reconstructing an anterior or posterior SCJ dislocation.^[11]

This study aimed to evaluate patients clinically and radiographically to assess the safety, effectiveness and patient satisfaction following the restoration of the SCJ dislocation by using a high-strength non-absorbable tape suture.

MATERIALS AND METHODS

From May 2020 to May 2022, a prospective case series study was conducted at the hospitals affiliated with Al-Azhar University (Al-Hussein, Bab El Shaerrya and Al-Azhar Damietta Hospitals) in Egypt, on ten patients (nine males and one female). Their average age was 40.1 years (18–52 years). They all had a symptomatic anterior SCJ dislocation confirmed by the clinical and radiographic investigations, four on the left and six on the right side [Figure 1]. They were treated with open reduction and reconstruction by high-strength non-absorbable tape sutures. This addressed the injury pattern and evaluated pain, range of motion,

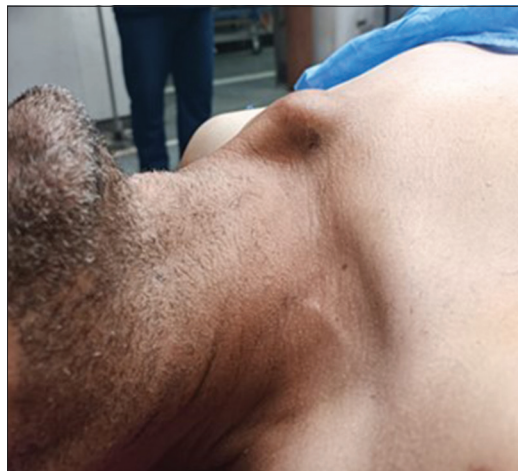

Figure 1: Deformity and swelling of the left sternoclavicular joint.

complications, functional outcomes, and patient satisfaction by simple shoulder testing using the American shoulder and elbow score (ASES) and the disabilities of the arm, shoulder, and hand (DASH) score.^[12,13]

Inclusion and exclusion criteria

All patients included in this study were symptomatic and had acute anterior SCJ dislocation within 3 weeks of the injury. Those with dislocation more than 3 weeks from injury were excluded from the study.

All patients were evaluated clinically for deformity, skin condition, range of motion, neurovascular status, and associated injuries. Four patients had isolated anterior SCJ dislocation, three had fractured ribs, one had hemothorax, one had pneumothorax, and the last had a distal radius fracture. Furthermore, routine anterior-posterior chest radiography, serendipity view and CT 3D were done for all patients [Figure 2].

The injury's mechanism was as follows: Five motor car accidents, three pedestrian collisions and the remaining two patients fell on their ipsilateral shoulder while playing football.

All patients were evaluated with the routine investigation (laboratory, chest radiograph, ECG, and echocardiography) cardiac, chest, and anesthesia consultations before surgery to check fitness for surgery and consent for the operation was taken.

Surgical technique

The same operative technique was used in all patients included in the current study using a high-strength non-absorbable tape suture [Figure 3].

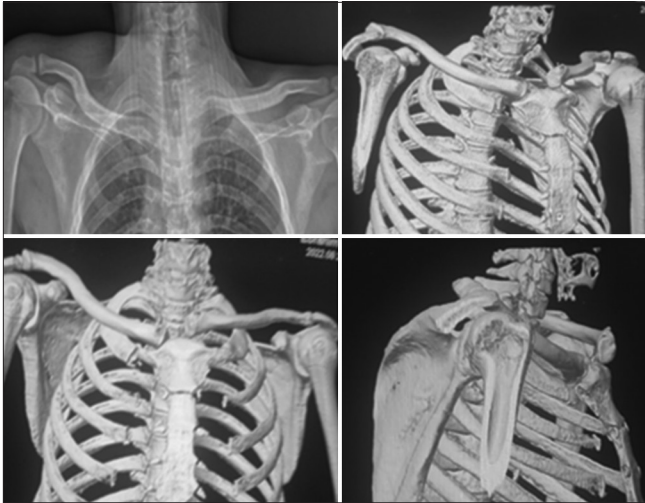

Figure 2: Plain radiography and CT 3D show dislocation of the left sternoclavicular joint.

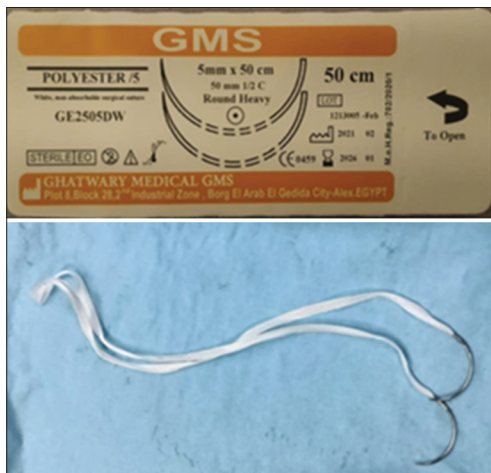

Figure 3: Tape suture used in reconstruction.

All patients were operated on under general anesthesia and were given prophylactic antibiotics with induction of anesthesia. All patients were positioned supine with the ipsilateral shoulder and arm free draped to be easy to move and manipulate during surgery to help in the reduction.

First, the identification of SCJ and marking-our planned incision was made (about 2 cm at each side of the joint to make about 4–6 cm incision). Next, skin, subcutaneous tissue, and platysma muscle were opened in line with the incision to be directly on the joint capsule. Then, we opened the capsule and started subperiosteal elevation of the tissue attached to the medial end of the clavicle, debriding it and removing the intra-articular disc [Figure 4]. Then, we made two holes with a drill about 1cm away from the end, allowing the needle to pass through with the tape [Figure 5].^[14]

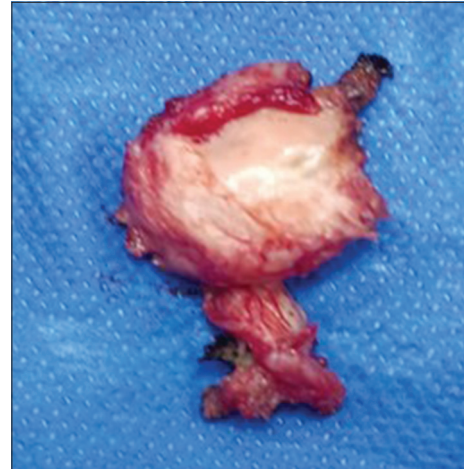

Figure 4: Excision of the articular disc.

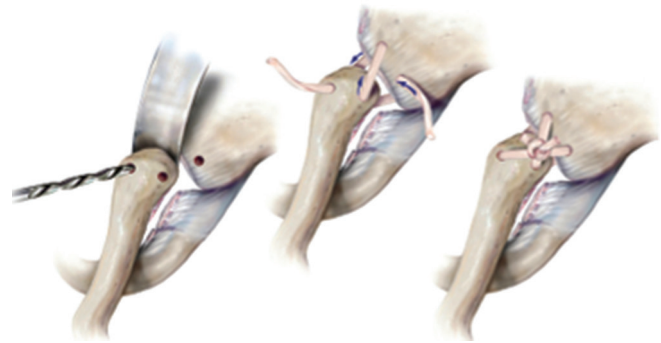


Figure 5: Sternoclavicular Joint Reconstruction. The tape suture is passing through holes in a figure-of-eight style and tied with suture knot.^[14]

We elevated the periosteum and tissue attached to the sternum to allow a good view of the articular notch. We also made two holes in the sternum to allow passage of a sharp cutting needle of the tape suture. We carefully took a good grip from the sternal side to avoid cutting through bone with the threads.

We started a trial of reduction without passing sutures. Then, after confirmation that it was acceptable, we passed heavy non-absorbable tape sutures starting from the hole on the clavicular end toward the sternum in a figure-of-eight configuration [Figure 6a-d] and secured it with a suture knot. Finally, we closed the capsule, approximated the periosteum, and closed the muscle and skin.

Post-operative

After immobilizing for 4–6 weeks, participants underwent range-of-motion exercises with slings and swathes. Sports involving contact are prohibited for 3–6 months. Radiological and clinical follow-up was done for all patients in the outpatient clinic and post-operative complications were documented.

Statistical analysis

The SPSS 16.0 application for Windows was used for the statistical analysis (Chicago, IL, USA, 2007). Categorical (qualitative) variables are shown as percentages, while continuous (quantitative) variables are provided as mean \pm SD. In addition, the Chi-square test (χ^2) was used to compare categorical variables between groups, whereas the analysis of variance test [paired *t*-test] compared continuous variables.

RESULTS

This prospective study included ten patients with a mean age of 40.1 years who presented with acute symptomatic anterior SCJ dislocation and were treated with reconstruction by high-strength non-absorbable tape sutures [Table 1].

The mean operative time was 78.5 min. Eight patients had reconstruction in the 1st week after injury, and the remaining

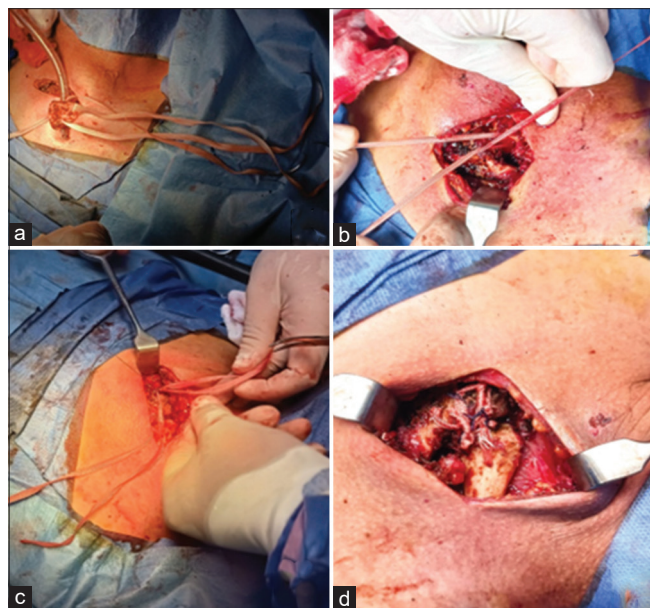


Figure 6: (a) Elevation of clavicular end and passage of tape, (b) Passage of the tape through the sternal end using the sharp tipped needle attached to the tape, (c) Tying tape and suturing using non absorbable threads, and (d) Suture knot.

Table 1: Patients demographics and clinical information (N=10).

Age	Sex	Side	Mechanism of injury	Associates in injuries
40.10 yrs. (18–52 yrs)	9 Male and 1 Female	6 Right and 4Left	5 MCA 3 Pedestrian 2 Sports injuries	4 Dislocation only 3 Fracture ribs 1 Pneumothorax 1 Haemothorax 1 Distal radius

MCA: Motor car accident

two patients had reconstruction 2 weeks after stabilization of pulmonary function, as one had a pneumothorax and the other had hemothorax. There was no intraoperative complication. The average follow-up time was 12 months (9–18 months).

The ASES^[12] showed an average improvement of physical function of 24.59, which is extremely significant as the pre-operative mean was 68.11 ± 3.72 while the post-operative mean was 92.70 ± 3.54 . Furthermore, the DASH questionnaire measured arm, shoulder, and hand impairments^[13] and showed extremely significant improvement as it decreased from 68.92 ± 4.38 preoperatively to 5.16 ± 2.91 postoperatively [Table 2].

Immediate post-operative radiographs [Figure 7] for all patients showed that all dislocated joints were effectively reduced.

On outpatient clinic follow-up, no redislocation had occurred. Only one patient had slight subluxation after 3 months, but it did not affect the shoulder function.

All patients had satisfactory results due to the disappearance of deformity, swelling, pain, and regaining of function and pre-injury activity level with no serious complication or injury to the near structures of the joint [Figure 8].

DISCUSSION

The SCJ, which is created by the clavicle, perching over the top of the sternum, and the medial end of the first rib, is a unique joint that is crucial in the transmission of force and smooth scapulothoracic motion during shoulder elevation. Strong extrinsic ligaments and a dynamic muscular envelope serve as primary stabilizers. Due to a lack of thorough literature on the issue, challenges in diagnosis, limitations of conventional radiography, unfamiliar anatomy, and complex biomechanics, it is a frequently neglected joint.^[15]

Since the posterior joint capsule is stronger and requires a 50% stronger power to dislocate the clavicle posteriorly, the SCJ joint is most frequently displaced anteriorly.^[16,17]

When an anterior SCJ dislocation reduces on its own, the arm is immobilized for 6 weeks while still in the sling in case the joint settles and stabilizes. A closed reduction under general anesthesia may be tried if the dislocation persists and is discovered within 7–10 days. If closed reduction was unsuccessful, the surgeon should proceed with surgical reduction.^[7]

Various surgical methods are described for the reconstruction of anterior SCJ dislocation documented in the literature, including biologic reconstruction using tendon autografts (sternocleidomastoid, palmaris longus, semitendinosus, and gracilis) and fascial loops^[7] or non-

Table 2: Comparison of pre and postoperative functional score.

Item	Preoperative		Postoperative		Correction means	P-value (Singnificance)
	Mean	SD	Mean	SD		
ASES	68.11	±3.72	92.70	±3.54	24.59	<0.00001 (ES)
DASH	68.92	±4.38	5.16	±2.91	63.76	<0.00001 (ES)

SD: Standard deviation, ES: Extremely significant. ASES: American shoulder and elbow score, DASH: Disabilities of the arm, shoulder and hand

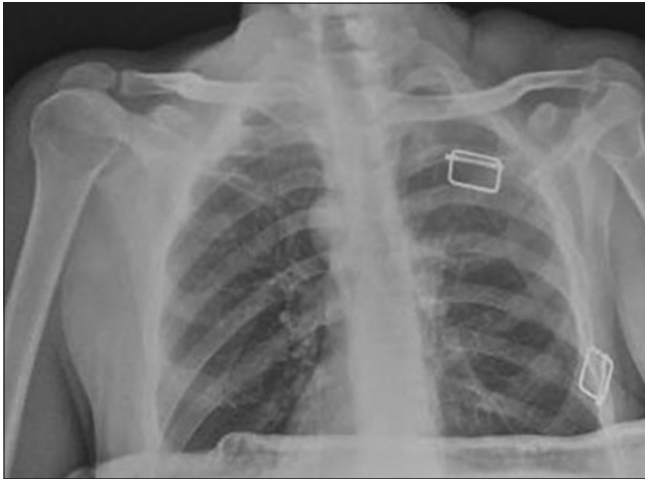


Figure 7: Postoperative plain radiograph show reduction of the left sternoclavicular joint.

biologic ligaments made of synthetic materials such as carbon fiber and dacron.^[18,19] Acromioclavicular joint hook plates, fiber wire, two screws, a T-plate, a locking plate, and a strong suture were also mentioned in the literature, along with using Kirschner (K) wires.^[7,20] Moreover, it was documented that resection of the sternal head of the clavicle without repair of the ligamentous tissues appears to be a poor option for treating SCJ instability. Last but not least, tenodesis of the subclavius tendon, sternal head of the sternocleidomastoid muscle, and myoplasty were also reported for treating SCJ dislocations.^[11]

The trachea, esophagus, brachiocephalic vein, brachiocephalic artery, and brachial plexus are significant thoracic structures behind the SCJ. They are safeguarded against unintentional injury caused by surgical intervention on the manubrium sterni, regardless of the surgical techniques used.^[3,21-23]

A systematic review reported that although 18 articles recommended having a cardiothoracic surgeon on standby during the operation, they found no instances, they were needed in the 35 cases of open reduction, leading them to the conclusion that the recommendation to have one on standby during an open reduction of an SCJ dislocation is, at best, weak.^[24]

Our surgeries were done in collaboration with the cardiothoracic surgeon, who was present in all cases guarding

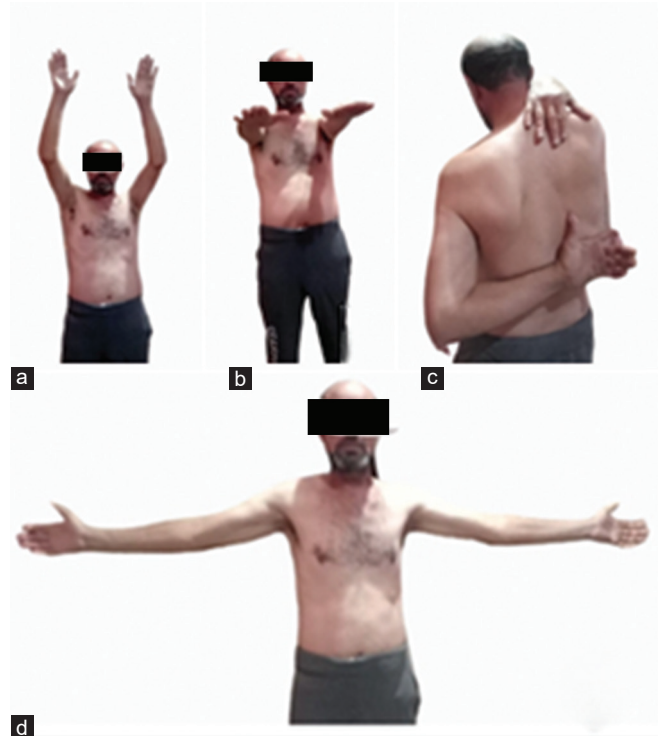

Figure 8: Functional result 6 months following the left anterior sternoclavicular joint repair.

against major complications. Therefore, it was a good option to work in a multidisciplinary team.

Full anterior dislocations necessitate better-fixing methods since they have a higher propensity to redislocate. The SCJ provides stability to the thoracic cage and the shoulder girdle's range of motion through clavicle rotation around its longitudinal axis and elevation at the SCJ of up to 40°. Due to its inflexible nature and these qualities, plating is not a good option for reconstructing the SCJ. Besides that, the disturbance of soft tissue during the implantation and removal of plates and the increased risk of metal fatigue and failure must be contemplated.^[9,25,26]

On the contrary, tendon grafts provide an alternate and more physiologic choice. Hence, most surgeons favor figure-of-eight restoration with a tendon graft (sternocleidomastoid, palmaris longus, gracilis, fascia lata, or semitendinosus tendon).^[26] The main disadvantages of tendon grafting include comorbidity, as well as the notion

that tendon grafts are vulnerable to early failure due to disintegration, rupture, and stretching, which could also lead to repeated SCJ instability.^[11]

We have similar results compared to Adamcik *et al.*^[27] which used a similar technique. However, with fiber wire in five cases presented with anterior and posterior SCJ dislocations, all patients showed improvement in terms of physical activity and return to the pre-injury activity level in the last follow-up. They also used the DASH score for evaluation of the activity of the patient post-operative, as we did in our patients.

In another study by Qu *et al.*^[20] they reconstructed anterior SCJ dislocation in ten patients by hook plates. They improved their average ASES score by 21.71 points, which was 68.11 preoperatively and 89.82 postoperatively. Moreover, it was similar to our result as the ASES in our patients had an average improvement of 24.59 points and changed from 68.11 preoperatively to 92.70 postoperatively.

Finally, our method for repair of anterior SCJ dislocation by a high-strength non-absorbable tape suture has many advantages compared to the other methods or techniques used for the reconstruction described in the literature (1) The suture is available, cheap, and easy to use. (2) Avoids donor site morbidity compared to biological reconstruction by tendon grafts. (3) Avoids injury to the vital structures behind the SCJ by screws or K-wires penetration used in other fixation methods. (4) Furthermore, the shoulder girdle may benefit from our method's provision of micromotion within a specific range between the clavicle and manubrium sterni. (5) Avoids hardware-related complications (skin irritation, infection, loosening, osteolysis, and infection). (6) The patient does not need a second operation to remove the hardware.

Strength and limitation

The study's positive aspects are that we used the same score of other institution performing reconstruction of SCJ dislocation for evaluation of the physical activity of the patient postoperatively (ASES and DASH). Hence, we can easily compare our results with them. However, the limitation of this study is a small number of patients, and this is because this injury is not common. Furthermore, the literature showed that the other studies reconstructing SCJ had fewer patients. Every study did reconstruction by a different technique. Most of the literature is case report studies that include one or two cases only.

CONCLUSION

Reconstruction of SCJ with high-strength non-absorbable tape suture (polyester) is simple, safe, and efficient, with good functional outcomes and high patient satisfaction.

Furthermore, it avoids other side comorbidities like autogenous grafts with few complications.

AUTHORS' CONTRIBUTIONS

MAAI, EA, GA, SA, conceived, designed the study and provided research materials. Also, they collected, organized data, analyzed, interpreted data and wrote the initial and final draft of the article. All authors have critically reviewed and approved the final draft and are responsible for the content and similarity index of the manuscript.

ETHICAL APPROVAL

The Al-Azhar Ethics Council of Al-Azhar University Hospitals authorized this research project. The registration number: Pat.3Med.Research.0000003 issued on 01/04/2020.

DECLARATION OF PATIENT CONSENT

The authors certify that they have obtained all appropriate patients consent forms. In the form, the patients have given their consent for their images and other clinical information to be reported in the journal. The patients understand that their names and initials will not be published and due efforts will be made to conceal their identity, but anonymity cannot be guaranteed.

FINANCIAL SUPPORT AND SPONSORSHIP

This study did not receive any specific grant from public, commercial, or not-for-profit funding agencies.

CONFLICTS OF INTEREST

There are no conflicting relationships or activities.

REFERENCES

1. Bae DS. Traumatic sternoclavicular joint injuries. *J Pediatr Orthop* 2010;30:63-8.
2. Botte MJ. Skeletal anatomy. In: Doyle JR, editor. *Surgical Anatomy of the Hand and Upper Extremity*. Philadelphia, PA: Lippincott Williams and Wilkins; 2003. p. 3-91.
3. Robinson CM, Jenkins PJ, Markham PE, Beggs I. Disorders of the sternoclavicular joint. *J Bone Joint Surg Br* 2008;90:685-96.
4. Wirth MA, Rockwood CA Jr. Disorders of the sternoclavicular joint. In: Masten FA, editor. *The Shoulder*. 4th ed. Philadelphia, PA: Saunders; 2009. p. 527-60.
5. Worman LW, Leagus C. Intrathoracic injury following retrosternal dislocation of the clavicle. *J Trauma* 1967;7:416-23.
6. Wirth MA, Rockwood CA Jr. Acute and chronic traumatic injuries of the sternoclavicular joint. *J Am Acad Orthop Surg* 1996;4:268-78.
7. Abiddin Z, Sinopidis C, Grocock CJ, Yin Q, Frostick SP. Suture anchors for treatment of sternoclavicular joint instability.

- J Shoulder Elbow Surg 2006;15:315-8.
8. Armstrong AL, Dias JJ. Reconstruction for instability of the sternoclavicular joint using the tendon of the sternocleidomastoid muscle. *J Bone Joint Surg Br* 2008;90:610-3.
 9. Burrows HJ. Tenodesis of subclavius in the treatment of recurrent dislocation of the sterno-clavicular joint. *J Bone Joint Surg Br* 1951;33B:240-3.
 10. Singer G, Ferlic P, Kraus T, Eberl R. Reconstruction of the sternoclavicular joint in active patients with the figure-of-eight technique using hamstrings. *J Shoulder Elbow Surg* 2013;22:64-9.
 11. Spencer EE Jr., Kuhn JE. Biomechanical analysis of reconstructions for sternoclavicular joint instability. *J Bone Joint Surg Am* 2004;86:98-105.
 12. Michener LA, McClure PW, Sennett BJ. American Shoulder and Elbow Surgeons Standardized Shoulder Assessment Form, patient self-report section: Reliability, validity, and responsiveness. *J Shoulder Elbow Surg* 2002;11:587-94.
 13. Beaton DE, Katz JN, Fossel AH, Wright JG, Tarasuk V, Bombardier C. Measuring the whole or the parts? Validity, reliability, and responsiveness of the Disabilities of the Arm, Shoulder and Hand outcome measure in different regions of the upper extremity. *J Hand Ther* 2001;14:128-46.
 14. Logan C, Shahien A, Altintas B, Millett PJ. Rehabilitation following sternoclavicular joint reconstruction for persistent instability. *Int J Sports Phys Ther* 2018;13:752-62.
 15. Athanatos L, Singh HP, Armstrong AL. The management of sternoclavicular instability. *J Arthrosc Joint Surg* 2018;5:126-32.
 16. Spencer EE, Kuhn JE, Huston LJ, Carpenter JE, Hughes RE. Ligamentous restraints to anterior and posterior translation of the sternoclavicular joint. *J Shoulder Elbow Surg* 2002;11:43-7.
 17. Aldosari AM, Bajuifer SJ, Bukhary HA. Migrated posterior sternoclavicular joint dislocation into the mediastinum along with clavicle diaphyseal fracture in a child. *J Musculoskelet Surg Res* 2021;5:128-31.
 18. Burri C, Neugebauer R. Carbon fiber replacement of the ligaments of the shoulder girdle and the treatment of lateral instability of the ankle joint. *Clin Orthop Relat Res* 1985;196:112-7.
 19. Kappakas GS, McMaster JH. Repair of acromioclavicular separation using a Dacron prosthesis graft. *Clin Orthop Relat Res* 1978;131:247-51.
 20. Qu YZ, Xia T, Liu GH, Zhou W, Mi BB, Liu J, *et al.* Treatment of anterior sternoclavicular joint dislocation with acromioclavicular joint hook plate. *Orthop Surg* 2019;11:91-6.
 21. Sewell MD, Al-Hadithy N, Le Leu A, Lambert SM. Instability of the sternoclavicular joint: Current concepts in classification, treatment and outcomes. *Bone Joint J* 2013;95-B:721-31.
 22. Rudzki JR, Matava MJ, Paletta GA Jr. Complications of treatment of acromioclavicular and sternoclavicular joint injuries. *Clin Sports Med* 2003;22:387-405.
 23. Clark RL, Milgram JW, Yawn DH. Fatal aortic perforation and cardiac tamponade due to a Kirschner wire migrating from the right sternoclavicular joint. *South Med J* 1974;67:316-8.
 24. Sernandez H, Riehl J. Sternoclavicular joint dislocation: A systematic review and meta-analysis. *J Orthop Trauma* 2019;33:e251-5.
 25. Glass ER, Thompson JD, Cole PA, Gause TM 2nd, Altman GT. Treatment of sternoclavicular joint dislocations: A systematic review of 251 dislocations in 24 case series. *J Trauma* 2011;70:1294-8.
 26. Castropil W, Ramadan LB, Bitar AC, Schor B, de Oliveira D'Elia C. Sternoclavicular dislocation-reconstruction with semitendinosus tendon autograft: A case report. *Knee Surg Sports Traumatol Arthrosc* 2008;16:865-8.
 27. Adamcik S, Ahler M, Gioutsos K, Schmid RA, Kocher GJ. Repair of sternoclavicular joint dislocations with FiberWire. *Arch of Orthop Trauma Surg* 2017;137:341-45.