

# Upper Limb Spasticity Surgery in Adults: What We Learned in 5 Years of Practicing it

Constantinos Kritiotis<sup>1,2</sup>, Marios Tryfonidis<sup>3</sup>, Anuj Mishra<sup>2</sup>, Haseem Raja<sup>4</sup>

<sup>1</sup>Department of Orthopaedic, Iasis Private Hospital, Paphos, <sup>3</sup>University of Central Lancashire, Larnaca, Cyprus, <sup>2</sup>Manchester Hand Centre, Salford Royal NHS Foundation Trust, Manchester, <sup>4</sup>Luton and Dunstable Hospital NHS Foundation Trust, Luton, UK

## ABSTRACT

We have been practicing surgical management of adult upper limb spasticity for the past 5 years. So far, we have evaluated 20 patients, and we have operated on nine patients with spasticity of the upper limb in Cyprus and the United Kingdom. We aim to present the setup and running of a new service, which is devoted to Surgery for Spasticity of the Upper Limb. We present our structure, organisational processes and service provision as well as our results in the nine cases that had surgical treatment as a part of their management (as well as our preferred techniques). We discuss our outcomes as well as our learning points from these cases. We also believe that selective neurectomy procedures can be very useful in the surgical management of upper limb spasticity. Tendon transfers to augment finger extension have a limited role and provide no significant benefits in adult spasticity cases. In addition, we found that the extensor carpi ulnaris transfer to extensor carpi radialis brevis has in our experience, reliable results regarding concentric wrist extension as well as easier rehabilitation. Furthermore, in severe cases, where no functional improvement is expected, joint fusions have a more predictable outcome. Spasticity reduction surgery does gain ground with the increase in survival of stroke patients as well as traumatic brain injury patients. Therefore, up to date methods for assessing, operating and evaluating postoperatively this category of patients need to be vigorously checked.

**Keywords:** Brain injury, neurectomy, spasticity, stroke, tendon transfer, upper limb

## INTRODUCTION

Spasticity of the upper limb due to a cerebrovascular incident (ischaemic, traumatic or haemorrhagic) may be a debilitating condition with multiple sequelae such as muscle tightness, joint stiffness, musculotendinous unit and/or joint contractures and joint deformities.<sup>[1]</sup> It may lead to the development of a number of troubling issues for patients, such as:

1. Hygiene problems
2. Functional abnormalities due to no use or spastic paralysis of the upper limb
3. Posture derangement due to the abnormal positioning of the upper limb
4. Pain.

Nonsurgical treatment methods may be used at the initial stages of spasticity development, usually in combination. These include regular physiotherapy, splinting with orthotic devices, muscle relaxant agents (such as Baclofen) or targeted botulinum toxin injections.<sup>[2,10]</sup>

The surgical treatment for upper limb spasticity and its sequelae may be considered after at least 1 year has elapsed after the time of brain injury, after conservative treatment has failed and when no further neurological recovery is expected.<sup>[15]</sup> Surgical treatment options include (a) soft-tissue surgery such as muscle or tendon lengthening, tendon transfers<sup>[3]</sup> and selective<sup>[4]</sup> or hyperselective<sup>[5]</sup> neurectomies or (b) bone/joint surgery such as joint fusions or bone excisions,<sup>[1]</sup> such as proximal row carpectomy (PRC). There may be a need for a combination of a number of the above categories of surgical techniques. Operative treatment is irreversible, and the results are permanent. Operative treatment aims to decrease, eliminate or redirect muscle forces, mobilise stiff joints, restore balance

**Address for correspondence:** Dr. Constantinos Kritiotis, Iasis Private Hospital, 8 Voriou Ipirou Street, 8036, Paphos, Cyprus. E-mail: kritiotis@gmail.com

Received : 10-12-2018

Revised : 26-12-2018

Accepted : 27-12-2018

Published Online : 18-02-2019

Videos Available on: [www.journalmsr.com](http://www.journalmsr.com)

Access this article online

Quick Response Code:



Website:  
[www.journalmsr.com](http://www.journalmsr.com)

DOI:  
10.4103/jmsr.jmsr\_83\_18

This is an open access journal, and articles are distributed under the terms of the Creative Commons Attribution-NonCommercial-ShareAlike 4.0 License, which allows others to remix, tweak, and build upon the work non-commercially, as long as appropriate credit is given and the new creations are licensed under the identical terms.

For reprints contact: [reprints@medknow.com](mailto:reprints@medknow.com)

**How to cite this article:** Kritiotis C, Tryfonidis M, Mishra A, Raja H. Upper limb spasticity surgery in adults: What we learned in 5 years of practicing it. *J Musculoskelet Surg Res* 2019;3:75-84.

to joints or stabilise joints, but it will not restore voluntary control to muscles or increase muscle force generation.<sup>[1]</sup> A similar concept of surgical treatment for upper limb spasticity is also used in cases of incomplete spinal cord injuries, but with a more advanced target of achieving a normalised pattern of grip as well as achieving an ergonomic manner of arm and shoulder work.<sup>[7]</sup>

Our main practice is based at the Republic of Cyprus, an island located in the Eastern Mediterranean. There are approximately 1000 acquired cerebrovascular incidents per year in the adult population. A significant percentage of those patients will go on to develop hemiplegic spasticity, which will alter their way of life. There is a great need for a holistic provision of spasticity care to these patients, including specialised upper limb surgical treatments when indicated, targeting towards improving the quality of life of these patients. The lead author also practices part time as a Consultant Hand Surgeon in the U. K. where he is involved in surgery of the spastic upper limb as well.

We present our experience and results in nine spasticity-reduction procedures that we carried out on nine patients, and we discuss our outcomes as well as our learning points from these cases. These patients were referred to our service either by rehabilitation doctors, physiotherapists or were self-referred.

## MATERIALS AND METHODS

### Setup of service

Patients were either self-referred or referred by their rehab team. Assessments we carried out using an in-house protocol.

### Pre-operative assessments

We developed an in-house protocol for each patient [Table 1], which includes the following:

1. Ashworth scale for spasticity
2. The classification of thumb in palm deformity
3. Medical Research Council grade of each muscle strength
4. Hoffer test
5. The evaluation of each individual muscle regarding its functionality (spastic, contracted, functional and flaccid).

Our outcomes regarding the functional improvement were measured using the House scale but as a part of continuing service development, we have introduced the Canadian Occupational Performance Measure (COPM),<sup>[8]</sup> which is a valuable tool in defining treatment priorities for individual patients and assessing the efficacy of intervention for that patient, both from a surgeon's and therapist's perspective as well as from the patient's perspective.

### Description of some of the surgical techniques used

Tables 2-4 provide a summary of the patient cases, description of the deformities tackled with surgical treatment and correction results following surgery. In the following paragraphs, we describe the main surgical techniques utilised for the patients' treatment. The techniques employed were mainly dependent on surgeons' preference, and this was based on training, experience and published literature when applicable.

**Table 1: Our evaluation pro forma for spasticity patients**

<b>Name</b>				
<b>Date of evaluation</b>				
<b>Botox (Yes/No/Muscles INjected)</b>				
<b>Modified ashworth scale</b>				
R/L	Muscle under stretch	Score with Ashworth Scale	The modified Ashworth scale	
	Biceps		0. No increase in muscle tone	
	PT		1. Slight increase in tone with a catch and release or minimal resistance at end of range	
	Wrist flexors		1+. As 1 but with minimal resistance through range following catch (less than half of the ROM)	
	FDS		2. More marked increase in tone through ROM	
	FDP		3. Considerable increase in tone, passive movement difficult	
	FPL		4. Affected muscle rigid	
	AD			
	FPB			
<b>Volkmans angle</b>				
<b>Joint range of motion, active and passive</b>				
R/L	Flex/Ext	Joint tested	Passive ROM	Active ROM
		Elbow		
		Wrist		
		Thumb IP		
<b>Muscle strength evaluation (MRC grade)</b>				
Muscle	MRC score			
Biceps				
Triceps				
Pronator teres				
BR				
Wrist extensors (ECRB, ECRL)				
Wrist flexors (FCU, FCR)				
EDC				
EPL				
FDS				
FPL				
FDP				
Supinators				
Intrinsics				
APL				
APB				
FPB				
AD				
SP: Spastic paralysis, FP: Flaccid paralysis, SVC: Spasticity but with voluntary control, NVC: Normal voluntary control				
<b>House classification of hand function (preoperative):</b>				
Class	Designation	Activity level		
0	Does not use	Does not use		
1	Poor passive assist	Uses as stabilizing weight only		

Contd...

**Table 1: Contd...**

Class	Designation	Activity level
2	Fair passive assist	Can hold on to object placed in hand
3	Good passive assist	Can hold object and stabilize for use by other hand
4	Poor active assist	Can actively grasp object and hold it weakly
5	Fair active assist	Can actively grasp object and stabilize it well
6	Good active assist	Can actively grasp object, stabilize it well and manipulate it against other hand
7.	Spontaneous use, partial	Can perform bimanual activities easily, occasionally uses hand spontaneously
8.	Spontaneous use, complete	Uses hand completely independently, without reference to the other hand

**Hoffer test: Less than 5s/More than 5s**

**Grading of thumb-in-palm deformity**

**House:**

**Tonkin:**

Degree of deformity	House classification	Tonkin classification	Description
Simple deformity	Type I		Spastic or contracted AP, first dorsal interosseous muscle or both
Intrinsic deformity	Type II	Type 1	Spastic or contracted AP, first dorsal interosseous or both, spastic or contracted FPB
	Type III		Spastic or contracted AP, first dorsal interosseous or both, compensatory action of EPL and EPB to the unstable MCP joint, absence of spastic FPL
Extrinsic deformity		Type 2	Spastic or contracted FPL, paretic EPL
Combined	Type IV	Type 3	Spastic or contracted AP, first dorsal interosseous or both, spastic or contracted FPB and FPL

The anaesthesia method in all the patients that we operated on was general anaesthesia with no peripheral nerve blocks.

All cases were operated as single stage, multilevel procedures.

### *Pectoralis major release*

We employed a rather simple approach for spasticity of the pectoralis major. We carried out this procedure when abduction and external rotation of the shoulder could not be passively achieved. Spasticity of this muscle can cause adduction and internal rotation deformity of the shoulder. Clinically, spasticity

of this muscle can be confirmed from the reduced external rotation of the shoulder in the abducted position, but most importantly, from the taut musculotendinous unit evident at the anterior axillary fold. In our approach, we use an L-shaped incision with the long limb of the L being directly over the taut pectoralis major tendon [Figure 1]. We sharply elevate the skin flaps off the musculotendinous unit and then utilise a z-plasty to elongate it until a significant correction of the internal rotation and abduction deformity can be observed. We find this to be the simplest, less technically demanding and less time-consuming procedure that can be employed for spasticity of the shoulder muscles. Postoperatively, the patient has to have the upper limb in abduction during rest but no abduction splints are utilised. In our limited series, the one patient that we carried out this procedure on did not develop any hygiene or other problems in the region of his axilla.

### *Biceps lengthening*

In our series of patients, we employed the commonly used Z-lengthening technique of the biceps tendon.<sup>[9]</sup> We used it in three patients, none of whom had functional elbow flexion.

### *Brachioradialis to extensor digitorum communis transfer*

This technique was used in two ischaemic stroke patients. The patient pre-operative upper limb function was clinically assessed with the elbow in resisted active flexion and neutral position. In this technique, the brachioradialis is elevated from its attachment to the radial styloid and mobilised all the way to the elbow, to increase its excursion up to 4 cm. It is then weaved in the extensor digitorum communis (EDC) in a side-to-side fashion and secured with 2.0 running Ethibond suture. Tension is set with the tenodesis effect. In our series, it failed to lead to the expected outcome (which was to augment the opening of the hand), although there may be a role in cerebral palsy patients with a very weak EDC.<sup>[10]</sup>

### *Total wrist fusion with proximal row carpectomy*

In two patients, we used the AO locking wrist arthrodesis plate (short bend), and in a third patient, we used the Medartis locking plate (straight wrist arthrodesis plate). In all patients, we also performed a PRC. We use the standard technique as advocated by AO. In all patients, the fusion improved the posture and stability of the wrist. This technique should be considered in non-functional hands and in patients with severe contracture of the wrist joint, where a tendon transfer will not adequately power enough the radial wrist extensors.<sup>[11]</sup>

### *1<sup>st</sup> Carpometacarpal joint fusion*

This technique is used in patients with instability of the joint and can also be used in patients with severe thumb-in-palm deformity. In this technique, the articular surfaces of the 1<sup>st</sup> carpometacarpal joint (CMCJ) are prepared, and a locking 2.0 t-plate can be used. The joint is fused in about 30° of extension and 30° of abduction so as for the thumb tip to pinch against the middle phalanx of the index. It can be combined

**Table 2: Patients operated by us**

A/A	PT	Age	Cause of spasticity	Date of brain injury	Pre-operative problems	Procedure	DOP	Remarks	Result
1	NS	50	Traumatic brain injury, Volkmann's contracture	2011	Claw hand deformity, subluxed 1 <sup>st</sup> CMCJ, HO left elbow	PRC and fusion left wrist Release of MCPJs, Fusion 1 <sup>st</sup> CMCJ, Zancolli Lasso	March 4, 2015	Ulnar nerve affected due to HO of elbow Video 1	Good grip and key pinch achieved. Reluctant to use unless necessary. House from 1 increased to 5
2	EV	40	Traumatic brain injury	1995	Clenched fist, spasticity of elbow, able to extend wrist (had FCU to ECRB in 2000)	Z-lengthening of FDPs (FDSs not found)	May 14, 2015	1. Had FCU to ECRB and FDPs lengthening in previous procedure 2. Unmasked intrinsic spasticity after the procedure 3. Had problems with hand hygiene preoperatively	Fingers managed to stay open, intrinsic spasticity kept MCPJs in flexion, no improvement in house classification, better hand hygiene achieved
3	AT	63	Ischaemic CVA	2013	Spasticity of biceps, PT, FDSs, thumb in palm deformity, clenched fist	Fractional Lengthening of FDSs, transfer of FDS 3 to rerouted EPL, transfer of FDS 4 to APL, BR to EDC, release of PT and thenar muscles, FCU tenotomy	September 30, 2016	1. Pre-operative Botox to FDS and thenar muscles with good results 2. Had long assessment period (6 months)	1. House improved from 2 to 4. Expectations of patient not met, BR to EDC did not help with finger opening
4	PA	58	Ischaemic CVA	2011	Spasticity of biceps, PT, FDSs, FPL, FDPs, thumb in palm, clenched fist	Fractional Lengthening of FDSs, FPL, FDPs, FDS3 to rerouted EPL, FDS4 to APL, BR to EDC transfer, release of PT, release of thenar muscles, tenotomy of FCU	October 3, 2016	1. Pre-operative Botox to FDS and thenar muscles, six months + assessment period, developed wound healing problems Videos 2-4	House improved from 2 to 3, happy with outcome, BR to EDC caused claw hand, FPL spasticity recurred
5	PD	19	Traumatic brain injury	2008	Spasticity of biceps, PT, FDSs, FPL, intrinsic type thumb in palm, FCU spasticity with ECU volar subluxation	Fractional lengthening of FDSs, FDPs in musculotendinous junction, ECU to ECRB transfer, FCU tenotomy, EPL rerouting, motor branch of ulnar nerve neurectomy, thenar muscle release	June 17, 2017	1. Had pre-operative nerve blocks to assess 2. Able to open fingers with extreme wrist flexion Videos 5-7	Significant improvement regarding spasticity reduction and functionality, has active finger opening, grasp and key pinch
6	PS	61	Haemorrhagic CVA	2016	Spasticity of biceps, PT, FDSs, intrinsic spasticity, spasticity of FCU bringing wrist to 90 100 degrees of flexion	Musculocutaneous nerve hyperselective neurectomy, lengthening of biceps tendon, flexor pronator slide, ulnar nerve motor branch neurectomy, PRC and total wrist fusion, intrinsic tenotomy	October 12, 2017	Assessed by two consultants (CK and AM) Operated in UK	No functional outcome was expected, goal was to reduce spasticity. General posture of upper limb improved except from fingers (now in clenched fist), for future FDS to FDP transfer

*Contd...*

Table 2: Contd...

A/A	PT	Age	Cause of spasticity	Date of brain injury	Pre-operative problems	Procedure	DOP	Remarks	Result
7	YS	34	Traumatic brain injury/ Spinal cord injury	2015	Fixed claw hand deformity, 1 <sup>st</sup> web space contracture, weakness of wrist extensors, subluxed ECU, mild FCU and FCR spasticity, contracture of volar wrist capsule	Release of finger and thumb MCPJs, release and lengthening of 1 <sup>st</sup> web space, BR to ECRL and ECU to ECRB, segmental lengthening of FCU and FCR and volar wrist capsule release	March 19, 2018	Video 8	Excellent functional, deformity fully corrected, significant improvement in grip and key pinch
8	GB	34	Hypoxic brain injury	2016	Spastic quadriplegia, low level of consciousness Spasticity in pectoralis major, biceps, FCU, FCR, FDPs, FDSs, PT, hygiene problems, intrinsic spasticity	Biceps tendon and brachialis lengthening, PRC and total wrist fusion, FCU and FCR tenotomies, FDSs to FDPs transfer, 1 <sup>st</sup> web space lengthening, motor branch of ulnar nerve neurectomy, FPL lengthening, intrinsic tenotomy	October 8, 2018	UK patient	Good outcome regarding upper limb posture, will consider pectoralis major release in surgery of the other upper limb
9	AK	15	Traumatic brain injury	2011	Left hemiplegia, spasticity of wrist flexors, PT, pectoralis major, biceps and long finger flexors	Release of pectoralis major, biceps lengthening, FDS, FPL, FDP lengthening, ECU to ECRB transfer, ECRB shortening, PT release, 1 <sup>st</sup> web space lengthening	October 22, 2018	Had previous surgery (FDP and FDS musculotendinous junction lengthening, FCU to ECRB transfer which caused volar subluxation of ECRB and ECRL) Picture 1	The aim was to reduce spasticity and improve posture - no functional outcome expected

CMCJ: Carpometacarpal joint, FCU: Flexor carpi ulnaris, FCR: Flexor carpi radialis, ECRB: Extensor carpi radialis brevis, ECRL: Extensor carpi radialis longus, PT: Pronator teres, FDS: Flexor Digitorum Superficialis, FPL: Flexor pollicis longus, FDP: Flexor digitorum profundus, MCPJ: Metacarpophalangeal joints, ECU: Extensor carpi ulnaris, EPL: Extensor pollicis longus, BR: Brachioradialis, APL: Abductor pollicis longus, CVA: Cerebrovascular accident, HO: Heterotopic ossification, A/A: Patient number

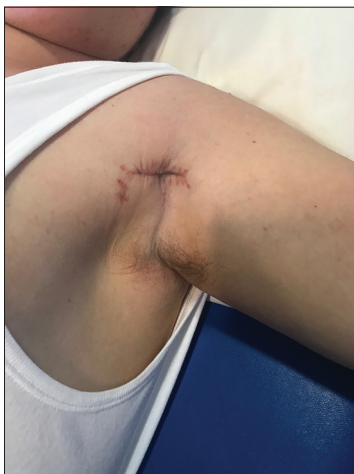

Figure 1: Incision used for pectoralis major release

with 1<sup>st</sup> web space lengthening. We believe that it has a place in elderly, post-ischaemic stroke patients as well.

### *Extensor carpi ulnaris to extensor carpi radialis brevis transfer for wrist extension*

This is our preferred method for achieving active wrist extension in spasticity patients. Usually, in spasticity patients, the extensor carpi ulnaris (ECU) is displaced volarly and despite being active, can contribute to the flexion deformity of the wrist [Figure 2]. One can identify the patients with the subluxed ECU from the hyperflexed and ulnarly deviated wrist. In this technique, the ECU is divided proximal to the subsheath in the Distal Radioulnar Joint; its muscle belly is mobilised and then weaved to the extensor carpi radialis brevis (ECRB).<sup>[14]</sup> This follows usually a segmental lengthening of both the flexor carpi ulnaris (FCU) and the flexor carpi radialis as well as release of the volar wrist capsule. We aim to keep the wrist in neutral when setting the tension and then the side-to-side weave is completed with a 2.0 Ethibond suture.<sup>[14]</sup> We believe it to be more predictable than the FCU to ECRB as the FCU is often found contracted. In addition, we do believe that rehabilitation will be easier as both donor and recipient are extensors and hence in-phase.

**Table 3: Summary of procedures used**

Procedure	n	Outcome	Recommendations
Wrist fusion with PRC	3	Good result regarding hand posture. All united	Consider for non-functional hands. PRC can help as an indirect tendon lengthening
1 <sup>st</sup> CMCJ fusion	1	Good result, achieved stable key pinch, thumb in palm deformity corrected	Consider for non-functional hands or severe instability of 1 <sup>st</sup> CMCJ
ECU to ECRB transfer	3	Two achieved good wrist extension which resulted in good functional outcome, third achieved keeping wrist in neutral (patient did not expect functional outcome)	Authors' preferred transfer for wrist extension
FDS, FDP and FPL musculotendinous junction lengthening (fractional lengthening)	3	Two patients had recurrence of spasticity to some extent, third maintained lengthening. Third patient who maintained lengthening had the fractional lengthening in two places of the musculotendinous junction instead of one	Spasticity may recur, technically easy. Consider lengthening in two places instead of one and immobilise for six weeks afterwards to prevent recurrence
FDS, FDP and FPL segmental lengthening	2	Good results in maintaining lengthening and preventing recurrence of spasticity. More technically demanding and time consuming than segmental (fractional) lengthening	Author's preferred method over fractional lengthening
Flexor pronator slide	1	Did not help with long finger flexors	Do not use as standalone procedure for FDS-FDP spasticity
EPL rerouting	1	Caused z-thumb deformity but maintained good web space opening	Consider with 1 <sup>st</sup> web space lengthening, attachment of EPL on MCPJ
BR to EDC transfer	2	Both patients failed to learn to fire the transfer. One had a claw hand deformity because of this transfer	Tendon transfers for EDC augmentation are in our limited experience not helpful
Pectoralis major release - lengthening	1	Technically easy to perform. Can work very well with arm posture, shoulder abduction and shoulder pain	Recommended in all patients that have pectoralis major spasticity. Consider release in female patients/lengthening in male patients
Motor branch of ulnar nerve neurectomy	3	In all patients it was successful in reducing intrinsic spasticity	Recommended in intrinsic spasticity as it is a reliable solution
Musculocutaneous nerve hyperselective neurectomy	1	Relatively new procedure, good for reducing spasticity of biceps	Recommended in patients with good functionality and in who the biceps fires during walking or during activities. Not indicated in spastic contracture
FDS to APL/EPL	4	Unpredictable transfer. Does not appear to offer functional benefits	Good as tenodesis procedure to keep thumb in abduction
Pronator teres release	5	Good supination achieved following release in all patients	Considered a spasticity trigger, should be released in all patients with pronation contracture
Biceps tendon lengthening	3	Improved elbow position in all patients	In our series, it was carried out in patients without function of the upper limb
FCU tenotomy	1	FCU tenotomy stopped the flexion deformity but caused an extension deformity	Consider lengthening instead of complete release to keep wrist in better positioning

PRC: Proximal row carpectomy, FCU: Flexor carpi ulnaris, FDS: Flexor Digitorum Superficialis, APL: Abductor pollicis longus, EPL: Extensor pollicis longus, CMCJ: Carpometacarpal joint, ECU: Extensor carpi ulnaris, ECRB: Extensor carpi radialis brevis, BR: Brachioradialis, MCPJ: Metacarpophalangeal joints, FDP: Flexor digitorum profundus

**Table 4: Patient categories and results**

Patient category/ cause of spasticity	Number	Mean age (years)	Results	Discussion
Ischaemic stroke	2	60.5	Fair	One patient not happy with outcome as it did not meet expectations. Older age may play a role with relearning and new synapses activation. Both patients had an increase on House scale by two
Traumatic brain injury	5	31.6	Good	All patients had reduction in spasticity of the upper limb. 4/5 had a functional improvement as well. Concomitant injuries and younger patient age play a role as well regarding outcomes
Haemorrhagic CVA	1	61	Good	Goal of procedure was reduction of spasticity, which was achieved to a great extent except for fingers
Hypoxic brain injury	1	34	Good	Goal of procedure was reduction of spasticity which was achieved to a great extent. FDS to FDP transfer appeared to improve finger posture significantly

FDS: Flexor Digitorum Superficialis, FDP: Flexor digitorum profundus, CVA: Cerebrovascular accident

### *Pronator teres release*

The pronator teres (PT) is spastic in the vast majority of spasticity patients. We prefer to use an incision over the radial

aspect of the mid-forearm. The PT tendon insertion to the radius is identified in the interval between the brachioradialis and the extensor carpi radialis longus (ECRL), and it is sharply

elevated with a 15-blade and periosteal elevator from the radial shaft. Then, the forearm is gently supinated until full supination is confirmed and the PT is retracted. We recommend release of the PT in all spasticity patients as we believe it to be a significant trigger of spasticity, although further research needs to be carried out to strengthen this point.

### *Long flexor tendon lengthening*

We employed two methods in our series. The first method was the musculotendinous junction lengthening (or otherwise known as ‘shark attack’). In this method, the tendon is cut in its origin, and then the finger is stretched, thus elongating the muscle/tendon unit. The other is to perform Z-lengthening of the flexor tendons and then a side to side repair [Figure 3, reproduced by permission<sup>[7]</sup>]. This method is more technically demanding and more time consuming than the ‘shark attack’ however, it has a lower rate of spasticity sequelae recurrence than the shark attack.

### *Motor branch of ulnar nerve neurectomy*

In this technique, a standard Guyon’s canal decompression is used in the hypothenar area of the palm, between the hook of the hamate and the pisiform.<sup>[6]</sup> Care must be taken not to mistakenly enter the carpal tunnel instead of the Guyon’s canal. Following that, the ulnar artery is gently retracted and protected and the adductor fascia is divided. Then, the motor branch of the ulnar nerve is identified as it crosses around the hook of the hamate. It is divided with electrocautery at this level. We believe that this is a very reliable technique when there is significant intrinsic spasticity as well as adductor and 1<sup>st</sup> dorsal interosseous spasticity. We use this technique in total non-functional contracture of both the intrinsic muscles as well as the adductor pollicis.

### *Intrinsic release*

When we have patients with significant contracture of the intrinsic muscles, we use a lazy-s incision over the dorsum of the finger, and we excise a triangular piece containing the lateral band and the oblique fibres, as advocated by Reinholdt and Fridén [Figure 4, reproduced with permission].<sup>[15]</sup>

### **Post-operative evaluation**

We evaluate all patients with the House scale. As mentioned above, with the development of the service, we introduced also the COPM. In addition, all patients have pre-operative and post-operative video evaluations to assess the improvement [Videos 1-8].

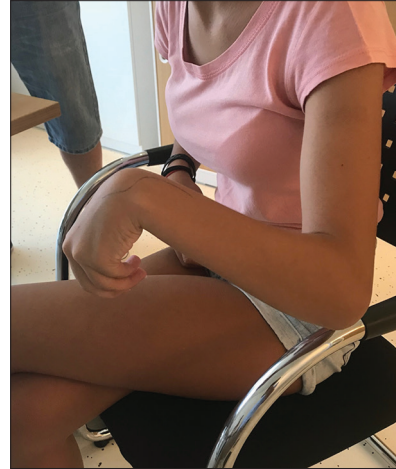## **DISCUSSION**

### **Patient groups and our recommendations**

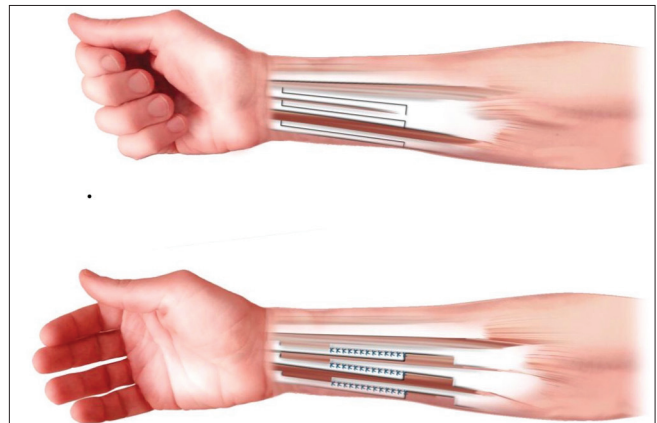
Patients with spasticity of the upper limb are a very challenging and constantly increasing population. In our population, we found that the demands for surgical treatment in upper limb spasticity are increasing with the spread of knowledge and surgical skills. We operated on four main categories of patients: (1) post-traumatic brain injuries, (2) patients following ischaemic stroke, (3) patients following haemorrhagic stroke

and (4) patients following hypoxic stroke [Table 4]. We did not include children with cerebral palsy in our study.

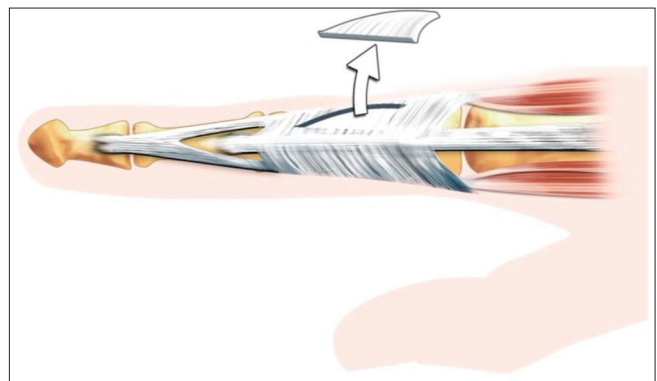
The majority of patients (five patients) that we operated on were sequelae from post-traumatic brain injuries. All patients required a number of consultation sessions, both not only for



**Figure 2:** Wrist in flexion and ulnar deviation. In this spasticity pattern, the extensor carpi ulnaris can be found subluxed volar to the midline, contributing to the flexion deformity of the wrist



**Figure 3:** Segmental lengthening of long finger flexors (image reproduced with permission from Carina Reinholdt)



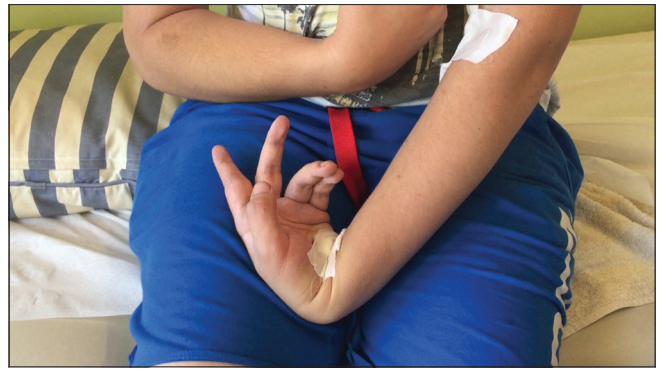**Figure 4:** Technique used for intrinsic spasticity (image reproduced with permission)

the surgeon to establish the patients' condition, disabilities, demands and expectations, but also for the patients and families to be counselled on the purpose of each proposed procedure, potential benefits and to agree on realistic target for surgical treatment. Pre-operative botulinum toxin injections or peripheral nerve blocks should be used to distinguish muscles with spastic contracture from muscles that have an increased tone but no contracture (and could be therefore used for a tendon transfer, like the FCU). The two ischaemic stroke patients received botulinum toxin injections approximately 6 months before their procedures to the FCU, Flexor Digitorum Superficialis (FDS) and thenar eminence. Patient PD received peripheral nerve block of the ulnar nerve (both in the cubital tunnel and the Guyon's canal) to evaluate his response to a possible motor branch ulnar nerve neurectomy [Video 6 and Figure 5].

In this patient series, we observed that patients following traumatic brain injuries composed the most varied population regarding their disability. The concomitant injuries (untreated fractures and dislocations, heterotopic ossification, spinal cord and brachial plexus injuries) have a significant impact on the way the deformity appears and therefore must be taken into consideration before the surgical procedure. In addition, the severity of the brain injury, even though it was not studied in our series, does appear to play a part in the severity of the spasticity. In our series, the best outcomes (both regarding function and spasticity reduction) were observed in this category of patients, and therefore, their younger age and possibilities for neurological recovery do play a significant part. Because of all these reasons, the spasticity pattern is different in each of these patients.

Ischaemic stroke patients should be considered a different category. They belong to a more senior age group (usually in their 7<sup>th</sup> decade of life), and they usually have significant comorbidities. Both patients with ischaemic stroke in our series suffered from a similar pattern of spasticity [Video 2]. More specifically, they had spasticity of the PT, the FCU and the long finger flexors (predominantly), as well as spasticity of the thenar muscles. No intrinsic spasticity was noted in any of the two patients. Both had totally absent EDC. Both were able to grasp but not to release. The results in our series were good regarding the reduction of spasticity but not regarding functional improvement, although on the House scale, they gained two points. Therefore, we recommend surgery for post-ischaemic stroke patients only when they had spasticity related hygiene problems or posture problems of the upper limb.<sup>[16]</sup> In addition, even though the idea of an augmenting tendon transfer for digital opening may sound tempting, due to the fact that these patients are difficult to retrain and also because they may have paretic intrinsics, it is not something that we would recommend.

Patients with massive haemorrhagic strokes may appear either with spastic hemiplegia or quadriplegia. Again, for this category of patients, we recommend surgery only for the purposes of reduction of spasticity. We do not recommend



**Figure 5:** Patient PD following peripheral nerve block injections of the ulnar nerve. Notice the improved posture of the thumb and the finger metacarpophalangeal joints

surgery for functional improvement, and any operative treatment should aim for a better posture of the upper limb, both for hygiene and daily care purposes.

Patients with hypoxic brain injury (e.g., post a prolonged cardiac arrest) have a diffuse pattern of brain injury and very often suffer from spastic quadriplegia. Again, we would not recommend surgery for functional improvement but rather for the reduction of spasticity and a better posture of the upper limb, which will help with the overall rehabilitation.

### **The procedures that we used and our recommendations**

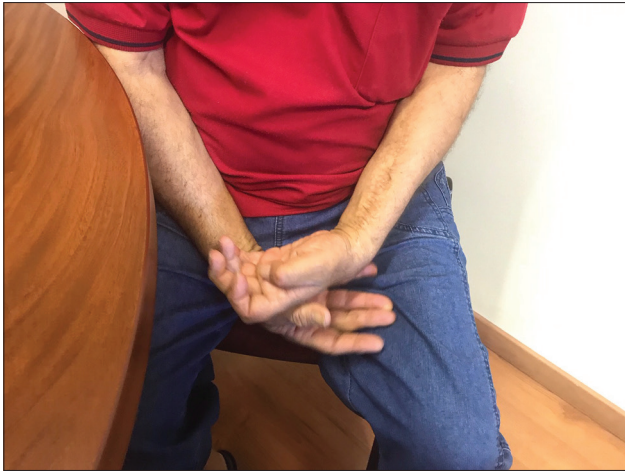As we presented above [Table 3], we used joint fusions, tendon transfers, tendon releases, tendon lengthening, selective neurectomies and joint fusions<sup>[13]</sup> in our series. Based on our outcomes, we have the following recommendations:

#### *Tendon transfers*

We are very much in favour of the ECU to ECRB transfer.<sup>[17]</sup> In our experience, it works very well, and it is an easily trainable tendon transfer (extensor for extensor). Furthermore, as the ECU is in the majority of the patients dislocated volarly (and therefore acts as a flexor) the deforming force is converted to a correcting force. We also believe that it is a more reliable transfer than the FCU to ECRB (Green's transfer), as the FCU is frequently severely contracted with absent voluntary control. Further research needs to be carried out to strengthen this point, but in our series, all ECU to ECRB transfers worked well. Should the surgeon wish to use the FCU, either for powering the wrist extensors or the finger extensor, a meticulous pre-operative examination should be carried out and also, the use of a motion laboratory should be mandatory to distinguish the spastic contracted FCU from the FCU that has an increased tone. We do believe that further research needs to be carried out to evaluate the superiority of ECU to ECRB transfer over the FCU to ECRB transfer.

We believe that the brachioradialis to EDC is not a reliable transfer for ischaemic stroke spasticity patients as it may either not work or create a claw hand deformity [Figure 6]. Our results with the use of this transfer were not satisfactory, despite meticulous pre-operative clinical examination





**Figure 6:** Secondary extension deformity of MCPJs post-brachioradialis to extensor digitorum communis transfer. This prevents the patient to wrap his hand around an object and achieve a stable grip

and evident function of the brachioradialis. However, we would recommend it for augmentation of wrist extension by transferring it either to the ECRL or the ECRB. We did transfer it to the ECRL of a patient with very weak wrist extensors (we also transferred the ECU to the ECRB), and the patient went on to achieve a very good extension of the wrist [Video 8].

The FDS III-IV to the Abductor Pollicis Longus and Extensor Pollicis Longus can in the worst scenario, create a good tenodesis for the thumb to keep it in abduction and extension; therefore, it can be considered in patients with severe thumb in palm deformity and no active EPL. However, care should be taken for possible wound healing problems (we had one in our series) if the transfer is very taut.

Finally, we recommend the FDS to FDP transfer for non-functional hands. In our practice, we buddy all the FDS tendons and all the FDP tendons in one unit (making sure that the finger cascade is maintained) and then weave the FDS unit through the FDP in a side-to-side fashion.<sup>[12]</sup>

#### *Tendon releases/lengthenings*

We believe that a spastic pronator quadratus must always be released. However, for the remaining spastic muscles, we recommend instead of releasing them to lengthen them. This will lead to a more balanced appearance of the affected joint(s) and preserve function if these muscles are active (like the long finger flexors).

#### *Joint fusions*

In our series, we fused one 1<sup>st</sup> CMCJ and three radiocarpal joints. Two out of the three radiocarpal joints fusions had non-functional hands, and the aim of the surgery was a better posture of the upper limb. We always combine this procedure with a PRC. All three cases of radiocarpal fusion united and the patients were happy with the posture of their hand. One of them had a functional improvement as well. Surgeons must take into account the fact that severity of the long finger flexors spasticity will cause the fingers to dig in the palm

when the wrist is fused in the extended position. We therefore recommend fusion in neutral position (using a straight wrist fusion plate)<sup>[11]</sup> and in non-functional hands to perform also an FDS to FDP transfer.<sup>[13]</sup>

The 1<sup>st</sup> CMCJ fusion was carried out in a traumatic brain injury patient with a traumatic dislocation of the 1<sup>st</sup> carpometacarpal joints, which was left untreated [Video 1]. It resulted in him getting a stable pinch and better posture of the hand. When carried out, we recommend also complementing it with a 1<sup>st</sup> web space lengthening.

#### **Selective neurectomies**

We only performed one motor branch of the ulnar nerve neurectomy in the Guyon's canal in a traumatic brain injury patient with severe spasticity of the intrinsic and the adductor pollicis.<sup>[4]</sup> Before performing the neurectomy, we did a peripheral nerve block of the ulnar nerve in the Guyon's canal to assess the functional improvement. We were very satisfied with the outcome as the patient did not develop a claw hand deformity and was able to perform a gross grip following the procedure [Videos 6 and 7]. Therefore, we believe that the indication for the motor branch of the ulnar nerve neurectomy is severe spasticity of the intrinsic muscles of the hand which may not improve by lengthening alone.

We also carried out a musculocutaneous nerve neurectomy in a post-haemorrhagic stroke patient with a severely contracted biceps (on which we also carried out a Z-lengthening of the biceps tendon).<sup>[5]</sup> We believe that this neurectomy has a role in an upper limb with a functional biceps to reduce the tone of the affected biceps and allow for function. However, we believe that it is not needed in patients who have a spastic and contracted biceps as it will not release the contracture. In these patients, with contracted non-functional biceps, we strongly recommend the Z-lengthening of the biceps tendon.

## **CONCLUSION**

We have presented our early experience and results in a newly established service in the Republic of Cyprus for spasticity surgery for the upper limb in adults. The benefits as well as pitfalls of various techniques were analysed, and recommendations based on our experience were discussed. We did learn a lot of lessons during this process, and as our experience grows, our results will hopefully, continue to improve.

Lessons learned are the following:

1. Use Patient-Recorded Outcome Measures (such as the COPM) to standardise and record outcomes
2. Further research needs to be carried out on the relation of the mechanism of brain injury and the subsequent spasticity pattern
3. We also recommend researching and publishing guidelines which will guide surgical treatment, based on:
  1. Type of brain injury
  2. Spasticity pattern, which will involve
    1. Spastic/contracted muscles

2. Muscles with increased tone
3. Active/functional muscles.

### Ethical consideration

We have obtained the written consent of the patients for the publication of their outcomes and their photographic material. Our institutions gave us the approval to proceed with this publication.

### Financial support and sponsorship

Nil.

### Conflicts of interest

There are no conflicts of interest.

### Author's contribution

CK conceived and designed the analysis, collected and analysed the data and wrote the paper. MT participated in data collection and co-wrote the paper. AM and HR contributed in data collection. All authors have critically reviewed and approved the final draft and are responsible for the content and similarity index of the manuscript.

### REFERENCES

1. Mikalef P, Power D. The rationale of operative treatment for spasticity of the upper limb. *MOJ Orthop Rheumatol* 2018;10:300-3.
2. Simpson DM, Patel AT, Alfaro A, Ayyoub Z, Charles D, Dashtipour K, *et al.* OnabotulinumtoxinA injection for poststroke upper-limb spasticity: Guidance for early injectors from a Delphi panel process. *PM R* 2017;9:136-48.
3. Fitoussi F, Bachy M. Tendon lengthening and transfer. *Orthop Traumatol Surg Res* 2015;101:S149-57.
4. Fouad W. Management of spastic hand by selective peripheral neurectomies. *Alexandria J Med* 2011;47:201-8.
5. Leclercq C, Gras M. Hyperselective neurectomy in the treatment of the spastic upper limb. *Phys Med Rehabil Int* 2016;3:1075.
6. Buffenoir K, Rigoard P, Ferrand-Sorbets S, Lapiere F. Retrospective study of the long-term results of selective peripheral neurotomy for the treatment of spastic upper limb. *Neurochirurgie* 2009;55 Suppl 1:S150-60. doi: 10.1016/j.neuchi.2008.04.003.
7. Wangdell J, Reinholdt C, Fridén J. Activity gains after upper limb surgery for spasticity in patients with spinal cord injury. *J Hand Surg Eur Vol* 2018;43:613-20.
8. Wangdell J, Fridén J. Rehabilitation after spasticity-correcting upper limb surgery in tetraplegia. *Arch Phys Med Rehabil* 2016;97:S136-43.
9. Mital MA. Lengthening of the elbow flexors in cerebral palsy. *J Bone Joint Surg Am* 1979;61:515-22.
10. Pinzur MS, Wehner J, Kett N, Trilla M. Brachioradialis to finger extensor tendon transfer to achieve hand opening in acquired spasticity. *J Hand Surg Am* 1988;13:549-52.
11. Neuhaus V, Kadzielski JJ, Mudgal CS. The role of arthrodesis of the wrist in spastic disorders. *J Hand Surg Eur Vol* 2015;40:512-7.
12. Hosalkar H, Pandya NK, Hsu J, Keenan MA. What's new in orthopaedic rehabilitation. *J Bone Joint Surg Am* 2011;93:1367-74.
13. Pomerance JF, Keenan MA. Correction of severe spastic flexion contractures in the nonfunctional hand. *J Hand Surg Am* 1996;21:828-33.
14. Fridén J, Tirrell TF, Bhola S, Lieber RL. The mechanical strength of side-to-side tendon repair with mismatched tendon size and shape. *J Hand Surg Eur Vol* 2015;40:239-45.
15. Reinholdt C, Fridén J. Selective release of the digital extensor hood to reduce intrinsic tightness in tetraplegia. *J Plast Surg Hand Surg* 2011;45:83-9.
16. Keenan MA. Management of the spastic upper extremity in the neurologically impaired adult. *Clin Orthop Relat Res* 1988;(233):116-25.
17. Trehan SK, Little KJ. Technical pearls of tendon transfers for upper extremity spasticity. *Hand Clin* 2018;34:529-36.