



## Case Report

# Epithelioid malignant peripheral nerve sheath tumor: A rare tumor with an unusual presentation in the ankle: A case report and literature review

Mohammed K. Alwhabi, MBBS<sup>1</sup>, Mohammad A. Almalki, MBBS<sup>2</sup> , Assem S. Alrumeh, MBBS<sup>1</sup>, Nasser M. Almadan, MBBS, BDS<sup>3</sup>, Salman A. Alfaifi, MBBS<sup>1</sup>

<sup>1</sup>Department of Anatomical Pathology, Central Laboratory and Blood Bank, Departments of <sup>2</sup>Orthopedic Surgery, <sup>3</sup>Dental, Oral Medicine and Pathology, Prince Sultan Military Medical City, Riyadh, KSA.

### \*Corresponding author:

Mohammad A. Almalki,  
Department of Orthopedic  
Surgery, Prince Sultan Military  
Medical City, Riyadh,  
KSA.

mohammad\_malki@hotmail.  
com

Received: 09 July 2022

Accepted: 05 September 2022

Epub Ahead of Print: 03 October 2022

Published: 18 November 2022

### DOI

10.25259/JMSR\_95\_2022

### Quick Response Code:



## ABSTRACT

Malignant peripheral nerve sheath tumor (MPNST) is a rare sarcoma with aggressive clinical behavior. Epithelioid MPNSTs (EMPNSTs) are distinct and rare variant of MPNST. They are described by the World Health Organization and they account for <5% of these tumors and have unclear clinical behavior. Due to the rarity of the EMPNST and the overlapping features and similarity with other tumors exhibiting epithelioid cytomorphology, EMPNSTs impose a diagnostic challenge. Therefore, it is critical to be aware of this entity and other mimickers to reach the correct diagnosis. Hence, this is a case of a 45-year-old lady who presented with persistent left ankle swelling for 2 years. A biopsy was performed, which confirmed the diagnosis of EMPNST. The aim of reporting this case of this rare tumor with this presentation was to help both pathologists and orthopedic oncology surgeons to understand the behavior of this tumor and help differentiate it from mimickers, and enrich interested readers' knowledge with the presented literature review.

**Keywords:** Ankle, Epithelioid, Malignant, Nerve sheath, Peripheral nerve, SMARCB1/INI1 gene, SOX10, S-100, Tumor

## INTRODUCTION

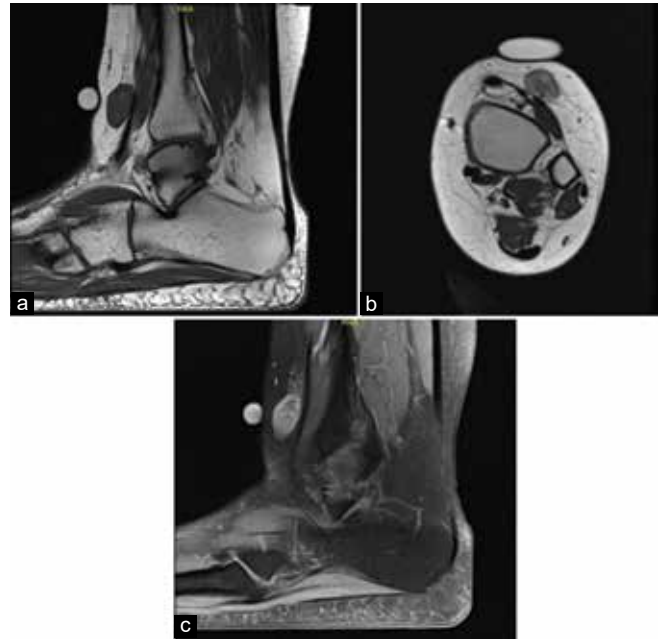Malignant peripheral nerve sheath tumor (MPNST) is a rare and aggressive sarcoma of the soft tissue, which occurs in around one in 100,000 of the general population.<sup>[1,2]</sup> MPNST is believed to originate from Schwann cells, with 50% of cases linked to neurofibromatosis Type 1 (NF-1), and 10% are associated with previous radiation exposure.<sup>[3]</sup> Epithelioid MPNST (EMPNST) is a rare subtype of MPNST (<5% of the tumors) and is distinct in molecular and morphology and immunophenotype.<sup>[4,5]</sup> EMPNST was initially reported in 1954 by McCormack *et al.*<sup>[6]</sup> It is the most common type to arise from ex-schwannoma, with no association with NF1.<sup>[5]</sup> EMPNST is most often present in the third or fourth decade of life with equal gender distribution. It most frequently arises in subcutis tissue of the lower extremity. MPNST is known to have aggressive clinical behavior with frequent metastasis and local recurrence. The lung is the most frequently affected site by metastasis, but other sites can also be involved. In the case of EMPNST, due to the scarcity of data and conflicting reports,

**How to cite this article:** Alwhabi MK, Almalki MA, Alrumeh AS, Almadan NM, Alfaifi SA. Epithelioid malignant peripheral nerve sheath tumor: A rare tumor with an unusual presentation in the ankle: A case report and literature review. J Musculoskelet Surg Res 2022;6:288-93.

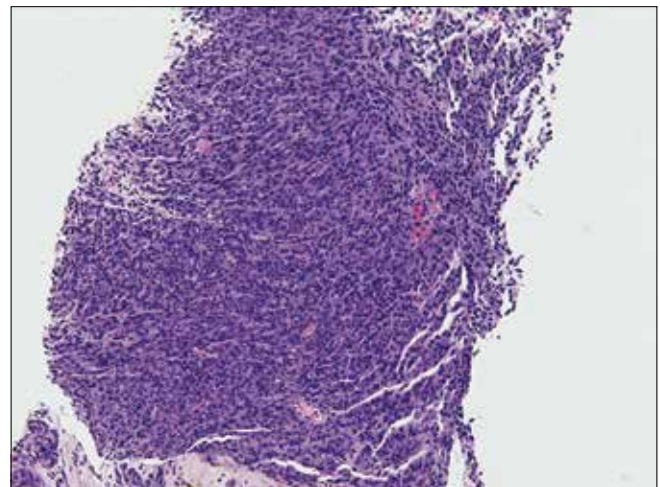
the clinical behavior is unclear. The main treatment method for these tumors is extended resection, but other treatment modalities have been proposed. These include adjuvant or neoadjuvant radiotherapy and chemotherapy. However, data are lacking to support these therapeutic modalities and whether they significantly improve that prognosis is still unknown.<sup>[7]</sup> In this paper, we report a rare case of EMPNST arising in an unusual location in the ankle, which was managed and resulted in favorable outcomes so far and we presented a literature review to enrich the paper and focus on differentiating this rare tumor from mimickers.

## CASE REPORT

A 45-year-old lady has been complaining of a slowly growing swelling in the left lower leg for the past 2 years. The swelling first started after an ankle sprain, where she developed persistent pain and tenderness. She experienced recurrent ankle sprains and increased swelling, growth, and tenderness during that time. She had cholecystectomy several years back but otherwise no other surgeries or significant medical history. She denied any family history of NF-1 disorder, clinical examination did not show signs of NF1 (café-au-lait spots, freckling of the axillae, or dermal neurofibromas). Initially, she visited the orthopedic clinic complaining of a limited ankle range of motion associated with tenderness. She was advised to rest and was prescribed nonsteroidal anti-inflammatory drugs (NSAIDs) with follow-up after 1 month. On the next visit, the swelling did not reduce and actually became larger, particularly at the anterior aspect of the left ankle. Magnetic resonance imaging was requested and it showed an oval-shaped soft-tissue mass lesion located at the anterior aspect of the left ankle. It measured about  $3.4 \times 1.7 \times 1.3$  cm and showed iso signal intensity on T1 with areas of high signal intensity, mixed high signal intensity in T2 with enhancement on post-contrast images. The mass was partially abutting the underlying flexor digitorum tendon. Imaging differential diagnosis included myxoid liposarcoma [Figure 1a-c]. Chest and body computerized tomography (CT) imaging were normal. A core needle biopsy was performed, and it demonstrated a hypercellular lesion with focal nodular and nesting patterns. It was composed of neoplastic cells showing epithelioid cytomorphology and moderate nuclear pleomorphism with prominent nucleoli. No evidence of heterologous/metaplastic elements was noted. Mitotic activity was present up to 10/10 high-power fields (HPF) and no necrosis was identified. The tumor showed strong and diffuse expression of S100 and SOX10 in the neoplastic cells [Figures 2-5]. They were negative for CD45, SMA, MyoD1, EMA, PAN-CK, CD34, Melan A, and HMB45. SMARCB1/INI1 expression was lost in tumor cells. However, the background stromal cells showed retained expression of SMARCB1/INI1. Ki67 index was 40–50% (in high spot areas) [Figures 6 and 7].

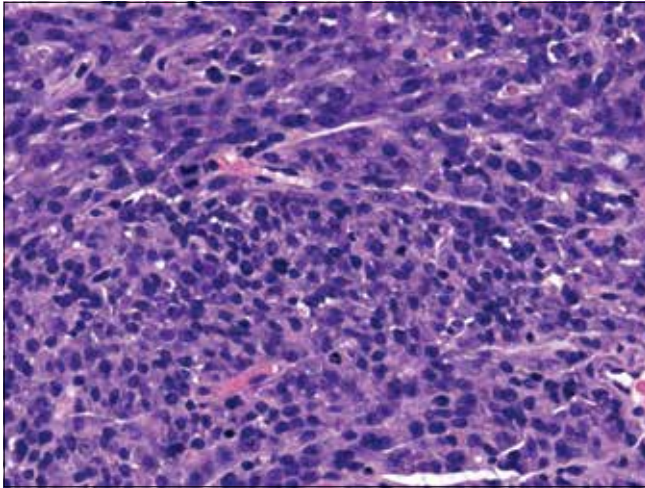


**Figure 1 :** (a) T1 MRI: Soft-tissue lesion at the anterior aspect of the distal left leg ( $1.3 \times 1.7 \times 3.4$  cm) and shows iso signal intensity on T1 with areas of high signal intensity, mixed high signal intensity in T2 with enhancement on post-contrast images. (b) T2 MRI: Soft-tissue lesion at the anterior aspect of the distal left leg ( $1.3 \times 1.7 \times 3.4$  cm) and shows iso signal intensity on T1 with areas of high signal intensity, mixed high signal intensity in T2 with enhancement on post-contrast images. (c) MRI post-contrast: Soft-tissue lesion at the anterior aspect of the distal left leg ( $1.3 \times 1.7 \times 3.4$  cm) and shows iso signal intensity on T1 with areas of high signal intensity, mixed high signal intensity in T2 with enhancement on post-contrast images.

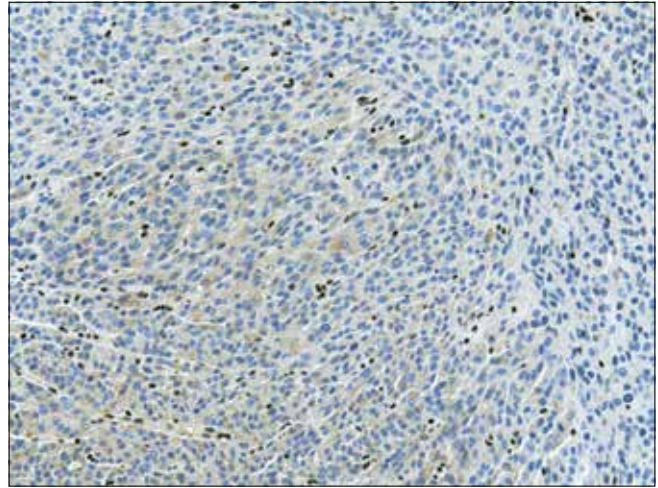


**Figure 2:** H&E 100×: Hypercellular lesion with nodular patterns composed of epithelioid neoplastic cells with moderate nuclear pleomorphism and prominent nucleoli.

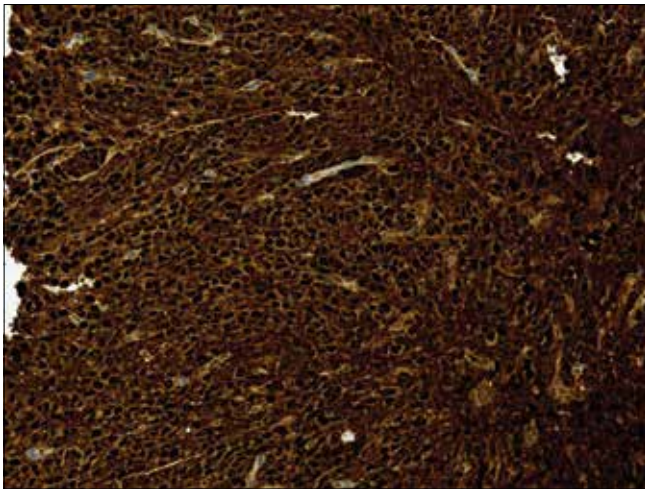
The histological and immunophenotypical features were in keeping with the EMPNST. The patient received



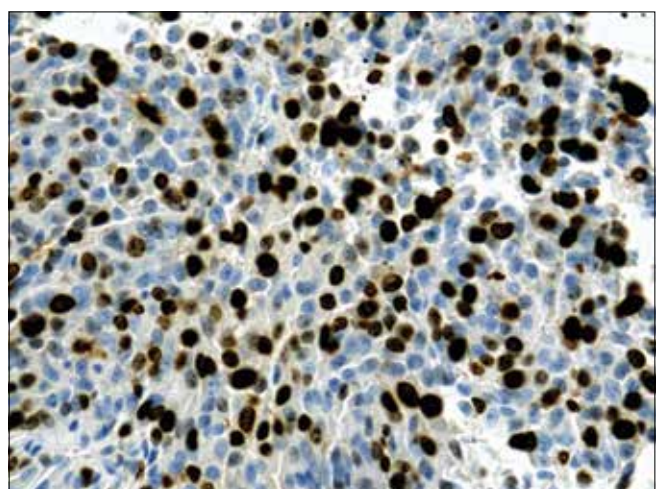
**Figure 3:** H&E 400x: The neoplastic cells show moderate nuclear pleomorphism and prominent nucleoli and high mitotic activity.



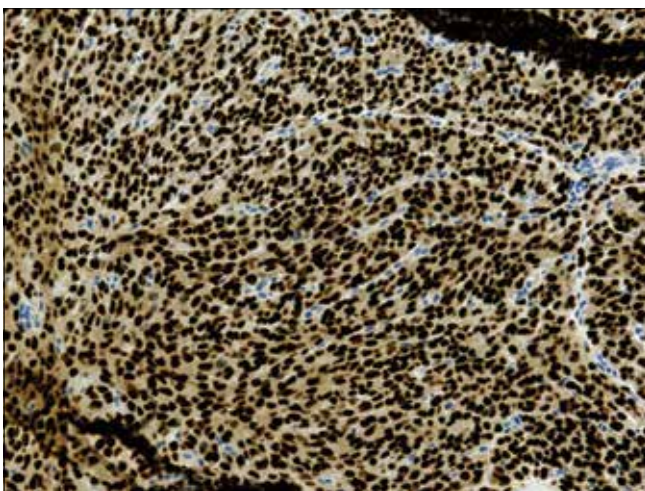
**Figure 6:** INI1 200x: SMARCB1/INI1 expression is lost in tumor cells.



**Figure 4:** S100 200x: The tumor is diffusely and strongly positive for S100 and SOX10.

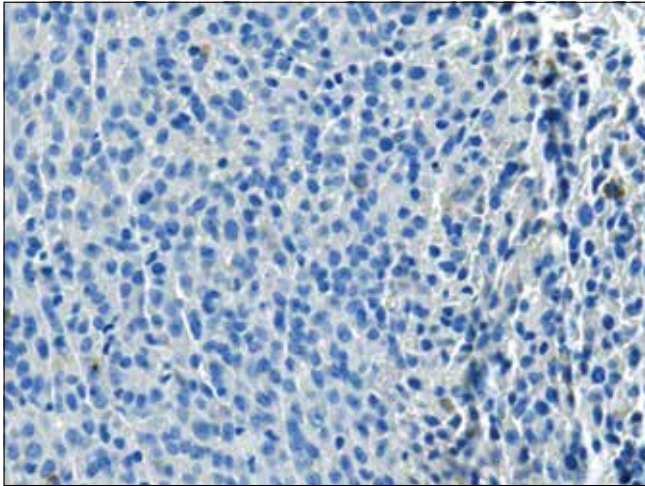


**Figure 7:** KI67 400x: High Ki67 index.

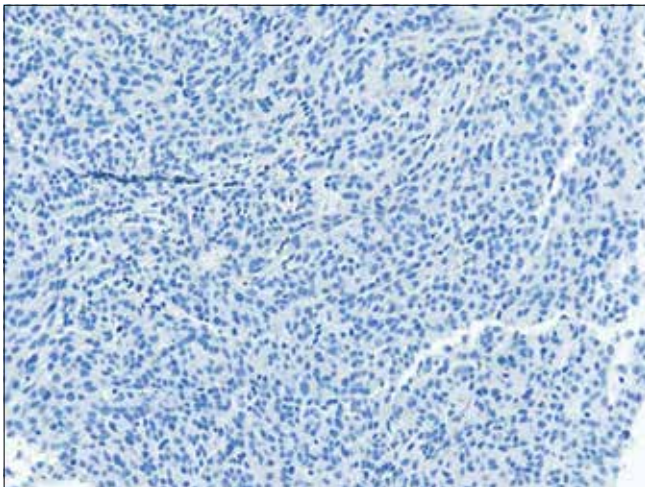


**Figure 5:** SOX10 200x: The tumor is diffusely and strongly positive for S100 and SOX10.

25 cycles of pre-operative radiotherapy and then had a wide excision of the tumor with a skin graft. Grossly, the tissue submitted for examination was an intact ellipse of skin with underlying soft tissue. The tumor was located superficial to the fascia and the skin surface was not involved. Sectioning revealed a well-defined, capsulated, tan-yellow, and heterogeneous mass measuring 4.0 × 1.2 × 1.0 cm. Neither necrotic nor hemorrhagic areas were observed. On the microscope, the neoplasm had similar morphological and immunophenotypical features as in the previous biopsy [Figures 8 and 9]. The tumor was mostly superficial to the fascia with a microscopic focus involving fascia and subfascial tissue. However, the margins were free of the tumor. To this date, 8 months of post-surgical intervention, the patient has not developed recurrence or metastasis. This has been ensured by following the patient regularly and excluding any complaints of any symptoms or pain related



**Figure 8:** Melan-A 200x: Tumor is negative for Melan A and HMB45.



**Figure 9:** HMB-45 200x: Tumor is negative for Melan A and HMB45.

to the surgical site and by imaging modalities including CT chest and abdomen and a whole-body bone scan to exclude recurrence or metastasis. The patient was advised to continue close follow-up with the oncology clinic.

## DISCUSSION

EMPNST is a variant of MPNST and differs in the morphological, molecular, and immunohistochemistry (IHC) staining pattern.<sup>[8,9]</sup> EMPNST most frequently arises in the subcutis of the lower extremity; however, other sites can be the primary origin of EMPNST, such as the trunk and deep visceral locations. As with our reported case, EMPNST manifests with predominant epithelioid cytology. The tumor displays circumscribed multilobulated solid sheet-like growth pattern in a

background of fibromyxoid stroma. The neoplastic cells commonly show prominent perivascular whirling, nuclear inclusions, multinucleated giant cells, and rarely rhabdoid cytology. In the tumor stroma, metaplastic elements (cartilage or bone) are known to exist.<sup>[5]</sup> Commonly traditional MPNST components can be found and may merge with the epithelioid component. Regarding IHC staining: Unlike classic MPNSTs, EMPNSTs ideally show strong diffuse expression of SOX10 and S100, highlighting the proposed Schwannian origin of these tumors.<sup>[10]</sup> Epithelioid MPNST may also be positive for keratin.<sup>[5]</sup> Another IHC characteristic of EMPNST is the loss of expression of SMARCB1/INI1 immunohistochemical stain. In contrast, classic MPNST demonstrates a distinctive loss of expression of H3K27me3 immunohistochemical stain, which is retained in EMPNST. SMARCB1/INI1 loss of IHC staining is demonstrated in 75% of EMPNST cases, which correlates with inactivating mutations in the tumor suppressor gene SMARCB1/INI1.<sup>[5]</sup> SMARCB1/INI1 gene is located at chromosome 22q and in 50% of EMPNST cases, there is a chromosomal copy number variations result in the deletions of chromosome 22q.<sup>[5,11]</sup> EMPNST lacks mutations in EED and SUZ12, which is demonstrated by the retained H3K27me3 expression in EMPNST when compared to H3K27me3 loss of expression in have of classic MPNST.<sup>[5,11]</sup> Less commonly, EMPNST can present without mutation in SMARCB1/INI1; in such cases, other mutations can be identified (NF1, NF2, TP53, and CDKN2A).<sup>[5,11]</sup> Our case demonstrates strong staining of S100 in the neoplastic epithelioid cells and the background spindle cells. However, INI1 loss was only identified in the epithelioid component and was retained in the background spindle cell component, which supports the proposed notion that EMPNST arises from Schwannian neoplasm [Table 1].<sup>[12]</sup>

Due to the rarity of the EMPNST and the overlapping features and similarity with other tumors exhibiting epithelioid cytology, EMPNST imposes a diagnostic challenge. To reach a correct diagnosis, it is critical to be aware of this entity and other mimickers. The differential diagnosis includes but is not limited to carcinoma, melanoma, myxofibrosarcoma, myoepithelial carcinoma, malignant rhabdoid tumor (MRT), epithelioid sarcoma, and epithelioid schwannoma. Starting with an IHC panel that includes cytokeratins, S100, Melan A, HMB45, and SMARCB1/INI1 can aid in distinguishing the aforementioned tumors. In the case of carcinoma, tumor cells typically exhibit cytokeratin positivity and S100 negativity. Myxofibrosarcoma more commonly occurs in the elderly. Distinct curvilinear vessels and vacuolated fibroblasts help in diagnosis and the tumor is S100 negative. Melanomas can be a challenge due to their varying morphological feature. However, they usually demonstrate more cytological atypia and typically express S100 protein, Melan A, and/or HMB45. Myoepithelial carcinoma can present with

**Table 1:** Variable differences between MPNST and EMPNST

	MPNST	EMPNST
Morphology	Spindle cells with fascicular growth pattern	Epithelioid cells with lobulated growth pattern
SOX10/S100	Patchy and focal	Strong and Diffuse
SMARCB1/INI1	Retained expression	Lost in 50-70%
H3K27me3	Lost in 50%	Retained expression
Associated mutations	SUZ12 and EED	SMARCB1/INI1

MPNST: Malignant peripheral nerve sheath tumor, EMPNST: Epithelioid malignant peripheral nerve sheath tumor

epithelioid cells forming cords and nest with myxoid stroma and architecturally mimic EMPNST. In addition, neoplastic cell stains for S100, which can be focal, CK, EMA, and a subset of these tumors, can be INI1 negative imposing further challenges. However, expression of smooth muscle markers and EWSR1 recurrent rearrangements with other fusion partners, including PBX1, ZNF444, and POU5F1, is characteristic of myoepithelial carcinoma and can aid in the diagnosis.<sup>[13-16]</sup> Epithelioid sarcoma stains strongly for cytokeratin, and in 50% of cases, it shows strong CD34 expression. MRT should be considered in the differential as they can have a similar morphology and immunophenotypic pattern. This tumor shows rhabdoid cytomorphology with loss of SMARCB1/INI1 expression. Thus, rendering cytogenetics and mutational analysis useless as both entities possess inactivating mutations in SMARCB1/INI1.<sup>[5,17,18]</sup> MRT generally displays a patchy positivity for S100, when, in fact, EMPNST shows diffuse and strong expression of S100.<sup>[4,19]</sup> Age can be helpful as MRT usually occur in children under 3 years, in contrast to EMPNST, which predominantly occurs in adults in the third and fourth decades.<sup>[4,8,20]</sup> Epithelioid schwannoma and EMPNST distinction are made on the bases of the extent of cytological atypia, mitoses, and the presence of necrosis. A subset of epithelioid schwannoma referred to as an atypical variant, can have some degree of nuclear atypia and an increased mitotic rate (up to nine mitoses per 10 HPFs).<sup>[21]</sup> Thus, criteria for malignancy should only include atypical mitoses and necrosis and caution should be exercised when dealing with increased mitosis.

The mainstay of the treatment of EMPNST is extended resection, companied with neoadjuvant/adjuvant radiotherapy. However, optimal excisional margins and the role of chemotherapy have not been established.<sup>[22-24]</sup> Loss of SMARCB1/INI1, which is similar to those occurring in epithelioid sarcoma and SMARCB1/INI1-deficient rhabdoid tumor, prompted the possible rule of enhancer of zeste homolog 2 (EZH2) inhibitors in the treatment of EMPNST. Studies examining the role of EZH2 inhibitors in patients with SMARCB1/INI1-deficient rhabdoid tumors and epithelioid sarcoma have shown improved survival.<sup>[25]</sup> Nevertheless, no study we are aware of has examined EZH2 inhibitors' effect on EMPNST and so far, no targetable therapies are available for EMPNST.

Mainly MPNSTs are regarded as high-grade sarcomas.<sup>[1]</sup> With local recurrence up to 40%, the overall 5-year survival rate was 34–43%.<sup>[4,26]</sup> Several prognostic factors were reported for MPNST, which include American Joint Committee on Cancer Stage III, size more than 10 cm, anatomic sites, resection margins status, negative S100 labeling, and increased Ki67 index (>25%), MDM2 and TP53 expression is all associated with inferior overall survival.<sup>[27]</sup> On the other hand, due to the rarity and limited literature on EMPNST, the biological behavior and prognosis are unclear. Furthermore, genetic findings and their prognostic values remain unclear in part to the small number of patients and the variation in survival rates.<sup>[4,26]</sup> The largest study with 63 cases of EMPNST by Jo and Fletcher showed a favorable outcome.<sup>[8]</sup> In contrast, other series demonstrated aggressive behavior.<sup>[8,28,29]</sup> One series demonstrated an aggressive clinical course of EMPNST, with seven patients out of 14 experiencing metastasis.<sup>[26]</sup>

## CONCLUSION

We report a case of EMPNST arising in the ankle. The clinical behavior of this lesion is unclear, but the largest series to this date reported favorable outcomes and a potential targeted therapy is on the horizon. It is of great importance to accurately diagnose this entity from other mimickers based on morphological, immunohistochemical, and molecular features.

## AUTHORS' CONTRIBUTIONS

MKW conceived the study and conducted the research. ASR provided research materials and collected and organized data. MAM wrote the initial and final draft of the article. NMM provided logistic support and SAF provided research materials and collected and organized data. All authors have critically reviewed and approved the final draft and are responsible for the manuscript's content and similarity index.

## DECLARATION OF PATIENT CONSENT

The authors' certify that they have obtained all appropriate patient consent forms. In the form, the patient has given her consent for her images and other clinical information to be reported in the journal. The patient understands that her name and initials will not be published and due efforts will be made to conceal her identity, but anonymity cannot be guaranteed.

## FINANCIAL SUPPORT AND SPONSORSHIP

This study did not receive any specific grant from funding agencies in the public, commercial, or not-for-profit sectors.

## CONFLICTS OF INTEREST

There are no conflicting relationships or activities.

## REFERENCES

- Høland M, Kolberg M, Danielsen SA, Bjerkehagen B, Eilertsen IA, Hektoen M, *et al.* Inferior survival for patients with malignant peripheral nerve sheath tumors defined by aberrant TP53. *Mod Pathol* 2018;31:1694-707.
- Feng CJ, Ma H, Liao WC. Superficial or cutaneous malignant peripheral nerve sheath tumor clinical experience at Taipei Veterans general hospital. *Ann Plast Surg* 2015;74 Suppl 2:S85-8.
- Ducatman BS, Scheithauer BW, Piepgras DG, Reiman HM, Ilstrup DM. Malignant peripheral nerve sheath tumors. A clinicopathologic study of 120 cases. *Cancer* 1986;57:2006-21.
- Laskin WB, Weiss SW, Bratthauer GL. Epithelioid variant of malignant peripheral nerve sheath tumor (malignant epithelioid schwannoma). *Am J Surg Pathol* 1991;15:1136-45.
- Schaefer IM, Dong F, Garcia EP, Fletcher CD, Jo VY. Recurrent SMARCB1 inactivation in epithelioid malignant peripheral nerve sheath tumors. *Am J Surg Pathol* 2019;43:835-43.
- McCormack LJ, Hazard JB, Dickson JA. Malignant epithelioid neurilemoma (schwannoma). *Cancer* 1954;7:725-8.
- Minagawa T, Shioya R, Sato C, Shichinohe R, Yasui G, Ishikawa K, *et al.* Advanced epithelioid malignant peripheral nerve sheath tumor showing complete response to combined surgery and chemotherapy: A case report. *Case Rep Oncol Med* 2011;2011:705345.
- Jo VY, Fletcher CD. SMARCB1/INI1 loss in epithelioid schwannoma: A clinicopathologic and immunohistochemical study of 65 cases. *Am J Surg Pathol* 2017;41:1013-22.
- Birindelli S, Perrone F, Oggionni M, Lavarino C, Pasini B, Vergani B, *et al.* Rb and TP53 pathway alterations in sporadic and NF1-related malignant peripheral nerve sheath tumors. *Lab Invest* 2001;81:833-44.
- Allison KH, Patel RM, Goldblum JR, Rubin BP. Superficial malignant peripheral nerve sheath tumor: A rare and challenging diagnosis. *Am J Clin Pathol* 2005;124:685-92.
- Schaefer IM, Fletcher CD, Hornick JL. Loss of H3K27 trimethylation distinguishes malignant peripheral nerve sheath tumors from histologic mimics. *Mod Pathol* 2016;29:4-13.
- Heatley N, Kolson Kokohaare E, Strauss DC, Hallin M, Jones RL, Fisher C, *et al.* Epithelioid malignant peripheral nerve sheath tumor arising in schwannoma. *Rare Tumors* 2020;12:2036361320950862.
- Hornick JL, Fletcher CD. Myoepithelial tumors of soft tissue: A clinicopathologic and immunohistochemical study of 101 cases with evaluation of prognostic parameters. *Am J Surg Pathol* 2003;27:1183-96.
- Thway K, Fisher C. Myoepithelial tumor of soft tissue: Histology and genetics of an evolving entity. *Adv Anat Pathol* 2014;21:411-9.
- Antonescu CR, Zhang L, Chang NE, Pawel BR, Travis W, Katabi N, *et al.* EWSR1-POU5F1 fusion in soft tissue myoepithelial tumors. A molecular analysis of sixty-six cases, including soft tissue, bone, and visceral lesions, showing common involvement of the EWSR1 gene. *Genes Chromosomes Cancer* 2010;49:1114-24.
- Huang SC, Chen HW, Zhang L, Sung YS, Agaram NP, Davis M, *et al.* Novel FUS-KLF17 and EWSR1-KLF17 fusions in myoepithelial tumors. *Genes Chromosomes Cancer* 2015;54:267-75.
- Biegel JA, Tan L, Zhang F, Wainwright L, Russo P, Rorke LB. Alterations of the hSNF5/INI1 gene in central nervous system atypical teratoid/rhabdoid tumors and renal and extrarenal rhabdoid tumors. *Clin Cancer Res* 2002;8:3461-7.
- Schofield DE, Beckwith JB, Sklar J. Loss of heterozygosity at chromosome regions 22q11-12 and 11p15.5 in renal rhabdoid tumors. *Genes Chromosomes Cancer* 1996;15:10-7.
- Burger PC, Yu IT, Tihan T, Friedman HS, Strother DR, Kepner JL, *et al.* Atypical teratoid/rhabdoid tumor of the central nervous system: A highly malignant tumor of infancy and childhood frequently mistaken for medulloblastoma: A Pediatric Oncology Group study. *Am J Surg Pathol* 1998;22:1083-92.
- Agaimy A. What is new in epithelioid soft tissue tumors? *Virchows Arch* 2020;476:81-96.
- Hart J, Gardner JM, Edgar M, Weiss SW. Epithelioid Schwannomas: An Analysis of 58 Cases Including Atypical Variants. *Am J Surg Pathol* 2016;40:704-13.
- Tsuchiya D, Takamura H, Saito K, Kashiwa H, Maeda K, Yamashita H. Immunohistochemical diagnosis of a rare case of epithelioid malignant peripheral nerve sheath tumor with multiple metastases. *Jpn J Ophthalmol* 2004;48:565-9.
- Hyodo T, Sugawara Y, Sakayama K, Kito K. Early-stage malignant peripheral nerve sheath tumour arising from a solitary neurofibroma. *Br J Radiol* 2012;85:e26-30.
- Hruban RH, Shiu MH, Senie RT, Woodruff JM. Malignant peripheral nerve sheath tumors of the buttock and lower extremity. A study of 43 cases. *Cancer* 1990;66:1253-65.
- Kusumoto E, Yamaguchi S, Sugiyama M, Ota M, Tsutsumi N, Kimura Y, *et al.* Huge epithelioid malignant peripheral nerve sheath tumor in the left axilla: A case report. *Surg Case Rep* 2015;1:64.
- Lodding P, Kindblom LG, Angervall L. Epithelioid malignant schwannoma. A study of 14 cases. *Virchows Arch A Pathol Anat Histopathol* 1986;409:433-51.
- Lee W, Teckie S, Wiesner T, Ran L, Prieto Granada CN, Lin M, *et al.* PRC2 is recurrently inactivated through EED or SUZ12 loss in malignant peripheral nerve sheath tumors. *Nat Genet* 2014;46:1227-32.
- Stockman DL, Miettinen M, Suster S, Spagnolo D, Dominguez-Malagon H, Hornick JL, *et al.* Malignant gastrointestinal neuroectodermal tumor: Clinicopathologic, immunohistochemical, ultrastructural, and molecular analysis of 16 cases with a reappraisal of clear cell sarcoma-like tumors of the gastrointestinal tract. *Am J Surg Pathol* 2012;36:857-68.
- Green C, Spagnolo DV, Robbins PD, Fermoye S, Wong DD. Clear cell sarcoma of the gastrointestinal tract and malignant gastrointestinal neuroectodermal tumour: Distinct or related entities? A review. *Pathology* 2018;50:490-8.