

## Original Article

## A case series for Enneking Stage III vertebral hemangiomas management, outcome, and literature review

Abdullah B Shabib, MBBS.<sup>1,2,3</sup>, Sami Aleissa, MD.<sup>1,2,3</sup>, Faisal Konbaz, MD.<sup>1,2,3</sup>, Anouar Bourghli, MD.<sup>4</sup>, Abdulrahman I. Alabdulkareem, MBBS.<sup>1,2,3</sup>, Monerah Annaim, MBBS.<sup>1,2,3</sup>, Fahad Alhelal, MD.<sup>1,2,3</sup>, Majed Abaalkhail, MBBS.<sup>1,2,3</sup><sup>1</sup>Department of Orthopedics, Ministry of National Guard Health Affairs, <sup>2</sup>King Saud Bin Abdulaziz University for Health Sciences, <sup>3</sup>King Abdullah International Medical Research Center, <sup>4</sup>Department of Surgery, Kingdom Hospital, Riyadh, Saudi Arabia.

## \*Corresponding author:

Faisal Konbaz,  
Ministry of National Guard  
Health Affairs, King Abdulaziz  
Medical City, Riyadh,  
Saudi Arabia.

faisal.konbaz@gmail.com

Received: 28 July 2021  
Accepted: 11 December 2021  
Epub Ahead of Print: 04 February 2022  
Published: 14 February 2022DOI  
10.25259/JMSR\_92\_2021

## Quick Response Code:



## ABSTRACT

**Objectives:** Vertebral hemangiomas are benign, slow-growing tumors. They represent 2–3% of spinal tumors and are incidentally found. Various treatment protocols have been described for Enneking Stage III vertebral hemangiomas. However, a comprehensive treatment protocol is still lacking. This case series aimed to describe the management of Enneking Stage III vertebral hemangiomas in two centers.**Methods:** This case series was performed by retrospectively reviewing the medical records of all patients diagnosed with Enneking Stage III vertebral hemangiomas at two centers in Riyadh, Saudi Arabia, from 2010 to 2020.**Results:** Eleven patients had Enneking Stage III vertebral hemangiomas. Mean follow-up was 47.5 ± 24.1 (range 9–120) months. All patients were symptomatic; the most common presentations were neurological deficits with or without myelopathy ( $n = 6$ ). Ten patients underwent surgical decompression with instrumentation. One patient refused surgery and underwent vertebroplasty and repeated sclerotherapy. All patients regained full neurological recovery during their follow-ups with a mean duration of 49.4 (range, 14–120) months. No recurrence was reported.**Conclusion:** In all 11 patients, they showed full recovery and clinical improvement regardless of treatment variety. Therefore, a larger study comparing various treatment methods is needed to reach a gold standard approach.**Keywords:** Spinal neoplasms, Surgical decompression, Surgical blood loss, Vertebroplasty, Hemangioma

## INTRODUCTION

Vertebral hemangiomas (VHs) are benign and slow-growing congenital vascular lesions. These are usually confined to the vertebral body rather than the posterior bony elements of the spine.<sup>[1-4]</sup> The most common location of these tumors is the thoracic spine followed by the lumbar spine.<sup>[2,5]</sup> However, unlike vascular malformations, VH does not have arteriovenous shunting.<sup>[2]</sup> VH represents 2–3% of spinal tumors, and they are incidentally found in up to 12% of the general autopsies.<sup>[1,6]</sup> VHs are asymptomatic in most of the population and are often an incident finding on imaging.<sup>[4]</sup> On plain radiography, the palisading appearance due to the**How to cite this article:** Shabib AB, Aleissa S, Konbaz F, Bourghli A, Alabdulkareem AA, Annaim M, *et al.* A case series for Enneking Stage III vertebral hemangiomas management, outcome, and literature review. *J Musculoskelet Surg Res* 2022;6:83-93.

thickening of bony trabeculae resembles “corduroy cloth.” Whereas on computed tomography (CT) scan, these tumors have low-density areas with bony tubercles, which resemble a “honeycomb” or a “polka dot” pattern.<sup>[7,8]</sup> Magnetic resonance imaging (MRI) is the most sensitive diagnostic modality for VH; typical VH exhibits high signal intensity on both T1- and T2-weighted sequences, whereas atypical VH exhibits high signal intensity on T2 with and low signal intensity on T1-weighted images.<sup>[7,9]</sup> VHs causing acute or subacute neurological symptoms are not common and are thought to be <1%.<sup>[2]</sup> Such hemangiomas are commonly known as aggressive VHs (AVHs). Neurological deficits that occur due to reduced interspinal space secondary to bony expansion are often seen in AVH. These tumors can exhibit extradural and dural extensions. VH rarely causes acute and subacute neurological deficits (in up to 45%) and/or pain.<sup>[10,11]</sup> In VH, the involved vertebra shows a trabecular pattern and that, by itself, preserves the vertebral function and resists the axial load; the compression fractures are, therefore, less common in comparison to other spinal tumors.<sup>[7,12]</sup> VH can be histologically classified into capillary, cavernous, and mixed subtypes. Furthermore, VH can be clinically classified according to the patients’ lesions and symptoms into type I, latent: Mild bony destruction without symptoms (Enneking Stage I, SI), type II, active: Bony destruction with pain (Enneking Stage II, SII), and type III, aggressive: Neurological deficit with epidural and/or soft-tissue involvement (Enneking Stage III, SIII).<sup>[13]</sup> In this article, Enneking SIII and AVH were used interchangeably.

Treatment of VH varies from conservative measures to aggressive surgical interventions depending on the severity of the presentation and the extent of the vertebrae and neuronal canal involvement. For symptomatic hemangiomas, transarterial embolization, radiotherapy, percutaneous injection of alcohol or methyl methacrylate, or surgical decompression are described in the literature.<sup>[14-18]</sup> Although there are a variety of treatment options described, controversial arguments exist. This paper aims to describe our experience in treating rare AVHs and the protocol that was followed by the authors and was not reported previously in the local literature.

## MATERIALS AND METHODS

### Patients

All consecutive patients with aggressive VHs were reviewed at King Abdulaziz Medical City and Al Mamlakah Hospital two centers in Riyadh, Saudi Arabia, from 2010 to 2020. The patients who met the following inclusion criteria were enrolled: Diagnosis confirmed on imaging; radiography, CT, and/or MRI, details on examination before any intervention, and Enneking

SIII VHs – severe back pain or neurological deficit with epidural and/or soft-tissue extension. Patients who had a follow-up duration shorter than 6 months and/or had an incomplete medical record were excluded from the study. The enrolled patients’ medical records were reviewed. Data retrieved included patient demographics, American Society of Anesthesiologists physical status classification score, pathological report pre-operative neurological status, tumor location, preoperative biopsy, pre-operative embolization, surgical procedure, estimated blood loss, complications, postoperative neurological status, and recurrence during the follow-up period. All data collections were approved by our Institutional Review Board.

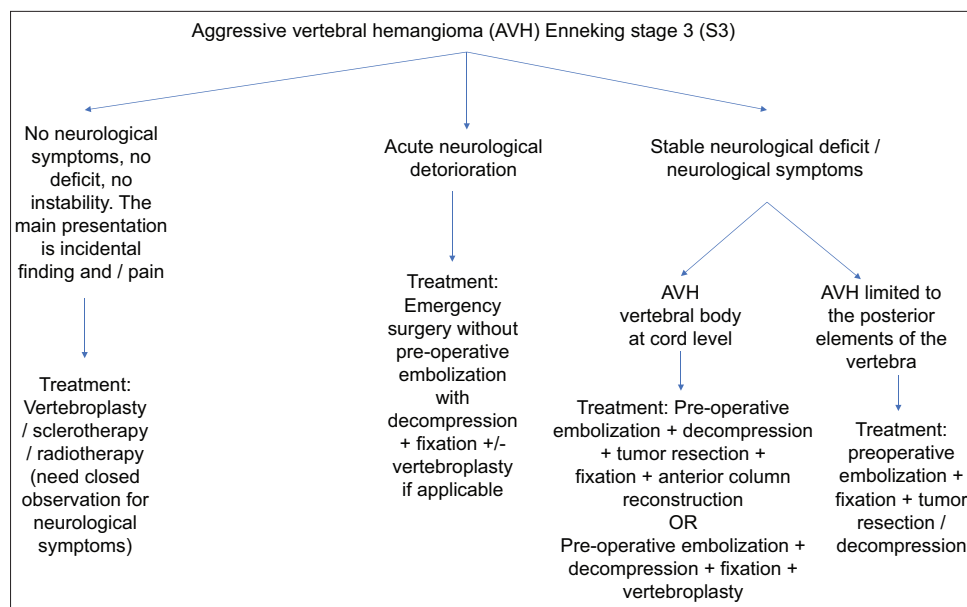
### Diagnosis and treatment protocol

The diagnosis protocol that was followed in our practice was based on patient symptoms and radiological features in the CT scan and the MRI. For patients who do not exhibit the common location or features of AVH, a CT-guided biopsy is indicated to rule out any suspected tumor other than AVH. For patients who do not exhibit neurological deficit and/or instability, non-operative treatment measures including vertebroplasty, sclerotherapy, and radiotherapy are proposed. The main surgical indications are neurological deficit, instability, and/or progressive symptoms of spinal stenosis. For patients who present with acute neurological deterioration, an emergent surgical decompression without pre-operative embolization is indicated with or without posterior instrumentation and vertebroplasty if applicable.

While patients who presents with a stable neurological signs and symptoms with features of spinal instability, they undergo preoperative embolization followed by surgical intervention. In this series, the surgical treatment and approach were decided based on various factors, including the primary surgeon experience, the location of the lesion, the extent of the spinal stenosis, and the success of pre-operative embolization. Various surgical treatment methods are utilized, including spondylectomy and posterior decompression with instrumentation with or without vertebroplasty. The treatment algorithm is summarized in [Figure 1].

### Follow-up

During follow-up, neurological status was evaluated using the American Spinal Injury Association impairment scale. In addition, patients were carefully observed for the recurrence of preoperative symptoms and complaints. Any patient who developed new signs and symptoms postoperatively underwent further imaging with MRI to confirm the recurrence.



**Figure 1:** Treatment algorithm for Aggressive Vertebral Hemangioma.

### Data collection and analysis

After acquiring approval from the Institutional Review Board, patients' data were collected from the hospital database. Quantitative variables were expressed as mean, standard deviation, and frequency.

### RESULTS

Eleven patients (seven males and four females) were included in the study; one female was in the postpartum period. The mean age was  $54 \pm 10$  years. The patients were diagnosed with thoracic spine hemangiomas ( $n = 8$ ) and lumbar hemangiomas ( $n = 3$ ). The most common clinical presentation observed was myelopathy ( $n = 6$ ). Two patients underwent pre-operative biopsy because of the atypical location of the tumor. Ten patients underwent surgical treatment, and one patient refused the surgical treatment and was treated with vertebroplasty and four sclerotherapy sessions over 7 years [Figures 2 and 3]. Six patients, who underwent preoperative embolization, had a mean blood loss of  $880 \pm 334.5$  mL, and five patients, who did not undergo pre-operative embolization, had a mean blood loss of  $650 \pm 313.75$  ml. All patients had resolution of their symptoms with full neurological recovery. Recurrence was only reported in one patient, who underwent vertebroplasty and repeated sclerotherapy. All patients were followed up for a minimum of 14 months, with a mean duration of 49.4 (range, 14–120) months. [Table 1] summarizes the patient data.

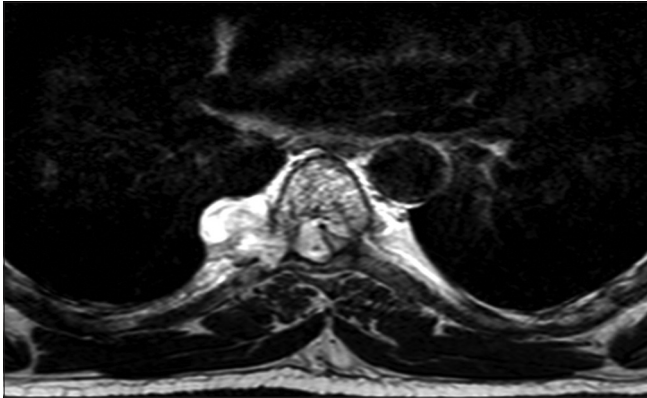
### DISCUSSION

Patients with symptomatic VHs (Enneking Stage II) mainly present with pain; the lesion does not involve the soft tissue

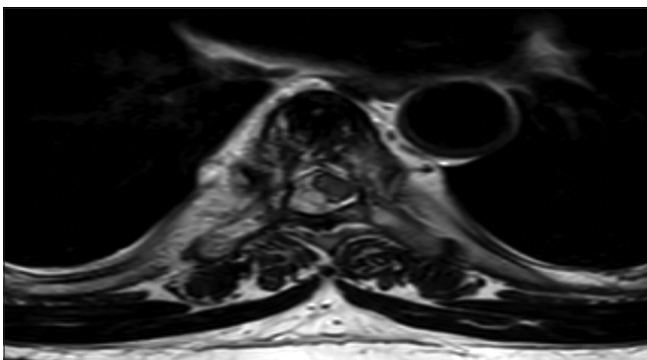
and is usually treated non-surgically with vertebroplasty and radiation therapy. However, approximately 45% of symptomatic patients develop neurological deficit (Enneking Stage III); the lesion causes spinal canal stenosis with soft tissue and often requires surgical intervention.<sup>[6,14,19-22]</sup>

Typical and atypical VHs differ only in histological composition; aggressive hemangiomas possess a different clinical behavior – they extend beyond the vertebral body and are associated with extensive cortical destruction.<sup>[1]</sup> In some instances, VHs might mimic primary and metastatic malignancies; pre-operative CT-guided biopsy, with a diagnostic accuracy of 89%, is highly recommended in such cases.<sup>[21,23,24]</sup> In this series, only two patients underwent pre-operative CT-guided biopsy due to the unusual location and radiological characteristics, thereby confirming the diagnosis of AVH.

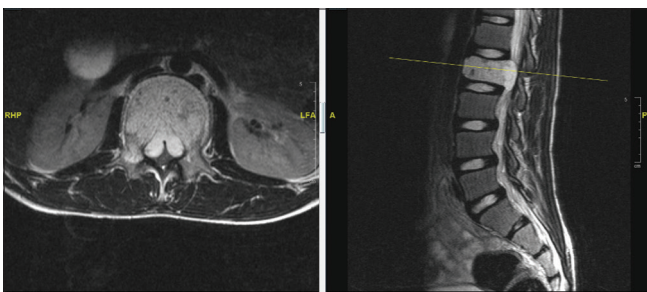
AVHs carry a high risk of bleeding, and thus for their treatment, pre-operative embolization is recommended.<sup>[25]</sup> Embolization helps identify main cord vessels, thereby preventing iatrogenic cord ischemia.<sup>[26]</sup> In 1972, Hekster *et al.* described the benefit of preoperative embolization in VHs. They reported a reduction in blood loss and observed a “decompressive effect” on embolization, causing relief in spinal cord compression.<sup>[27]</sup> In a recent meta-analysis, Robinson *et al.* reported less bleeding in patients who underwent pre-operative embolization.<sup>[28]</sup> Furthermore, surgical invasiveness, type of anesthetic drug, and hemostatic ability of the body also play a role in intraoperative bleeding. In our cohort, five patients did not undergo pre-operative embolization as they presented with acute neurological deficits that necessitated urgent surgical intervention without further delay. Higher mean blood loss was noted in the pre-



**Figure 2:** Pre-vertebroplasty and sclerotherapy MRI of T6 vertebral body in 2011, of a 58-year-old male presenting with back pain, who underwent vertebroplasty and four sessions of sclerotherapy over a 7-year period until his symptoms resolved.

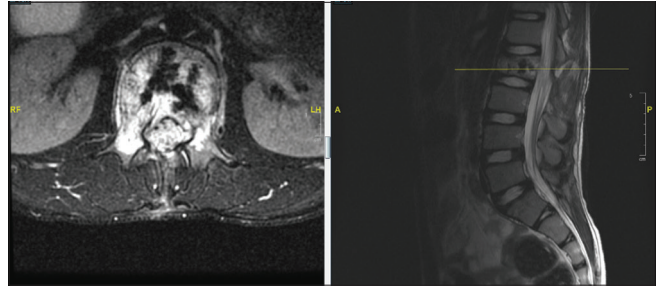


**Figure 3:** Post-last session of sclerotherapy in 2019 with complete symptoms resolution of a 58-year-old male presenting with back pain, who underwent vertebroplasty and four sessions of sclerotherapy over a 7-year period until his symptoms resolved.

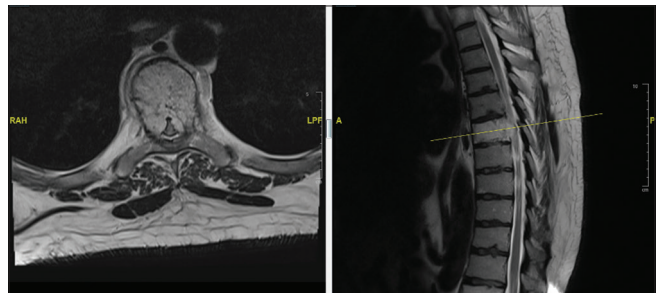


**Figure 4:** Pre-operative MRI images of a pediatric patient undergoing decompression without instrumentation with alcohol injection and vertebroplasty.

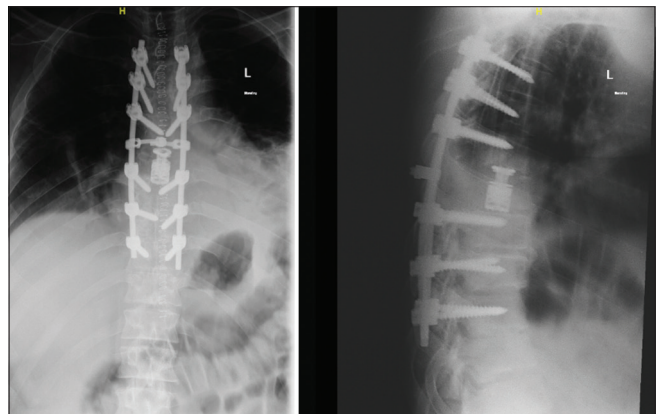
embolized group that is most likely attributed to the aggressive nature of the surgical procedure performed in our case series. Some reports have recommended using gelatin sponge for hemostasis, as it has shown promising and reliable results, along with benefits, such as reduced cement leak with vertebroplasty, low recurrence rate, and short operative time [Table 2].<sup>[1,19,22]</sup>



**Figure 5:** MRI in 1 year follow-up of pediatric patient, undergoing decompression without instrumentation with alcohol injection and vertebroplasty.



**Figure 6:** Pre-operative MRI images of a 54-year-old male who presented with neurodeficit and myelopathy, treated with T7 spondylectomy and reconstruction.



**Figure 7:** Post-operative X-rays of a 54-year-old male who presented with neurodeficit and myelopathy, treated with T7 spondylectomy and reconstruction.

The surgical intervention aims to decompress the neuronal elements and stabilize the vertebral segment. The location of VH and the rate of neurological deficit progression dictate the surgical procedure and surgical approach (anterior vs. posterior). AVH, however, typically invades the entire vertebral segment and is associated with soft-tissue extension, thereby compromising the structural integrity and stability of the involved vertebrae.<sup>[29]</sup>

Four patients presented with acute neurological deterioration in our institution, requiring emergent surgical

Table 1: Patient data summary.

S. No.	Gender	Age	ASA	Location	Pre-operative CT-guided embolization biopsy	Pre-operative embolization	Procedure	Pre-operative symptoms	Pre-operative ASIA score	EBL (cc)	Post-operative symptoms	ASIA on last F/U	Follow-up	Complications	Recurrence
1.	Male	17	III	T 8-9 Spinous process+ soft tissue	No	No	DC+PI	Neurological deficit+ myelopathy	C	1100	Resolved	E	55 months	None	None
2.	Male	12	I	L2 Vertebral body	No	No	DC w/o instrumentation +alcohol injection VP	Conus medullaris syndrome	D	300	Resolved	E	120 months	None	None
3.	Male	56	II	T9 Vertebral body	No	Yes	PI+ Spondylectomy +Titanium cage	Myelopathy	D	700	Resolved	E	14 months	None	None
4.	Male	31	-	T7 Vertebral body	No	Yes	Spondylectomy via thoracotomy/posterior approach+ Mesh cage +PI	Neurological deficit & myelopathy	C	-	Resolved	E	105 months	None	None
5.	Female	54	II	T12 Vertebral body	No	Yes	PI +Spondylectomy +titanium cage	Instability pain+ pathological fracture	E	1500	Resolved	E	21 months	None	None
6.	Male	54	III	T7 Vertebral body	No	Yes	PI+ Spondylectomy through Thoracotomy +titanium cage	Neurological deficit+ myelopathy	D	1100	Resolved	E	17 months	PE	None
7.	Female	60	II	L3 Spinous process	Yes	Yes	DC+PI	Back pain +neurogenic claudication	E	400	Resolved	E	25 months	None	None
8.	Male	58	II	T6 Vertebral body	Yes	N/A	SCP+VP Followed repeated SCP (x4)	Back pain	E	N/A	Resolved	E	109 months	None	Yes
9.	Female	60	III	L3 Vertebral body	No	Yes	PI+ scoliosis correction +DC+VP	Scoliosis+back pain+ neurogenic claudication	E	700	Resolved	E	23 months	Incidental durotomy	None

(Contd...)

Table 1: (Continued).

S. No.	Gender	Age	ASA	Location	Pre-operative CT-guided biopsy	Pre-operative embolization	Procedure	Pre-operative symptoms	Pre-operative ASIA score	EBL (cc)	Post-operative symptoms	ASIA on last F/U	Follow-up	Complications	Recurrence
10.	Female	30	I	T6 Vertebral body	No	No	DC+PI+VP	Neurological deficit+ myelopathy	C	800	Resolved	E	37 months	Distal junctional kyphosis	None
11.	Male	41	II	T7 Vertebral body and lamina +T9 Vertebral body	No	No	DC+PI+VP	Neurological deficit+ myelopathy	D	400	Resolved	E	18 months	No	None

EBL: Estimated blood loss, DC: Decompression, VP: Vertebroplasty, SCP: Sclerotherapy, PI: Posterior instrumentation, PE: Pulmonary embolism, ASA: American Society of Anesthesiologist

decompression without pre-operative embolization. Of which, three patients underwent vertebroplasty during the index procedure. Chen *et al.* did not perform pre-operative embolization in AVH patients with signs of acute instability and neurological deficit.<sup>[26]</sup> In our previously mentioned cases, vertebroplasty was utilized in the setting of acute neurological decompression as an intraslesional thromboembolic agent to decrease blood loss. In a previous study, Wang *et al.* compared the blood loss between patients who underwent decompression with intraoperative vertebroplasty and those who underwent decompression only. They injected bone cement intraoperatively to obliterate feeding vessels within the vertebral bodies. The results suggested a significant reduction in blood loss in the vertebroplasty group.<sup>[30]</sup> In addition, Zhang *et al.* and Dang *et al.* stated that vertebroplasty could eliminate the requirement of pre-operative embolization, as the cement served as an intraslesional thrombotic agent and thus reduced blood loss. In addition, vertebroplasty provided structural support for the treatment of AVHs.<sup>[14,31]</sup>

Posterior spinal decompression is a convenient and widely accepted technique. In cases of circumferential spinal cord compression, Fox and Onofrio reported a good outcome with posterior decompression. However, when the lesion encompassed the vertebral body, the spinal cord needed to be decompressed anteriorly. Pre-operative embolization and radiotherapy were also recommended post-subtotal tumor resection.<sup>[1]</sup> Corniola *et al.* proposed a multidisciplinary approach for the treatment of AVHs.<sup>[32]</sup> The treatment, including one-stage intraoperative percutaneous sclerotherapy and vertebroplasty followed by laminectomy, epidural injection, and subtotal resection of the epidural lesion, yielded excellent outcomes without complications in patients with AVH. In our series, six patients underwent posterior decompression, out of which two had posterior element lesions. In all patients, complete resolution of pre-operative neurological deficits and no recurrence were reported [Figures 4 and 5]. Thus, posterior decompression is an appropriate technique for a lesion that is limited to the posterior element or an anterior spinal tumor with posterior extension.

Although VHs are benign, partial resection has been associated with a 2.9–30% recurrence rate in patients with AVHs.<sup>[19,25,29]</sup> Therefore, some institutions advocate more aggressive intraslesional resection to minimize the risk of local recurrence.<sup>[28]</sup> In a paper published in 2011, Acosta *et al.*<sup>[29]</sup> argued that conservative surgical interventions, such as vertebroplasty, laminectomy, decompression, and instrumentation, were usually associated with a high recurrence rate in patients with Enneking SIII VH. They advocated the treatment, including pre-operative embolization, spondylectomy, complete tumor excision, and

Table 2: A literature review.

S. No.	Authors	No. of Pts	Presentation	Pre-operative embolization	Treatment	Mean follow-up	Complications	Recurrence
1.	Hu <i>et al.</i> (2018) <sup>[2]</sup>	5	Back pain+Myelopathy	None	DC+VP+Fusion	17.60 months	1 Asymptomatic cement leak	-
2.	Corniola <i>et al.</i> (2020) <sup>[32]</sup>	5	3 Myelopathy 2 Mechanical pain	2	3 had SCL+VP+DC+Epidural injection 2 had had SCL+VP+DC+Epidural injection+Fusion <i>En-bloc</i>	12 months	1 Seroma; treated conservatively	None
3.	Kato <i>et al.</i> (2010) <sup>[34]</sup>	5	-	All	<i>En-bloc</i>	135 months	None	None
4.	Goldstein <i>et al.</i> (2015) <sup>[25]</sup>	68	82 Back pain 20 Pathological Fx 25 Myelopathy 11 Cauda equina	35%	81% DC with PA 6% DC with AA/PA 10% Adjuvant RT	3.9 years	None	3%
5.	Wang <i>et al.</i> (2018) <sup>[30]</sup>	39	31 Myelopathy 4 Cauda equina 3 Radiculopathy 18 Back Pain	None	17 DC 22 DC+VP	50.2 months	1 Intraoperative dural sac tear with successfully repaired	1
6.	Xu <i>et al.</i> (2020) <sup>[9]</sup>	13	10 Mechanical pain 5 Myelopathy 2 Radicular pain 7 Pathological Fx	All	Group A: DC+VP (6 Pts) Group B DC+VP+AGSI (7 Pts)	62 months	None	None
7.	Xinran Ji. <i>et al.</i> (2020) <sup>[33]</sup>	23	21 Back pain+Myelopathy 2 Radiculopathy	21	<i>En bloc</i> spondylectomy (TES)	51.4 months	1 Pleural effusion resolved with closed drainage 1 Pneumonia treated with antibiotics	None
8.	Nair <i>et al.</i> (2012) <sup>[17]</sup>	7	4 Myelopathy+Radiculopathy 3 Myelopathy+Bowel/Bladder incontinence	None	5 Corpectomy+Cage+Fusion 3 DC+Fusion	24 months	2 Post-operative bleeding	None
9.	Jiang <i>et al.</i> (2014) <sup>[35]</sup>	21	15 Myelopathy 1 Cauda equina 5 Radiculopathy	None	variable	51.1 months	2 Extensive bleeding (Pts had spondylectomy)	3
10.	Prabhuraj <i>et al.</i> (2019) <sup>[37]</sup>	5	5 Gait issues 3 Back pain 4 Neurological complaints	All had glue embolization	DC ± Fusion	12–48 months	None	None
11.	Acosta <i>et al.</i> (2011) <sup>[29]</sup>	10	10 back pain 6 Myelopathy 1 Myelopathy+Kyphosis	All	Intralesional spondylectomy+Cage+Fusion	2.4 years	1 Post-operative PE 1 Dura tear 3 Post-operative medical complications 1 Superficial wound infection	None

(Contd...)

Table 2: Continued).

S. No.	Authors	No. of Pts	Presentation	Pre-operative embolization	Treatment	Mean follow-up	Complications	Recurrence
12.	Huang <i>et al.</i> (2020) <sup>[22]</sup>	17	15 Myelopathy 11 Back pain 2 Radiculopathy	All	VP+DC+Fusion+AGSI	64.0 months	None	None
13.	Gitardo <i>et al.</i> (2019) <sup>[38]</sup>	10	3 Back pain 7 Back pain+Neurological compromise (ASIA A-D)	All	DC+VP+Short segment Fusion	7.2-2.3 years.	None	2
14.	Vasudeva <i>et al.</i> (2016) <sup>[36]</sup>	5	1 Myelopathy 1 Postpartum Back pain 1 Back pain+Claudication	4	1 <i>En-bloc</i> 2 STR ± VP 2 GTR+VP	31 months	<i>En bloc</i> Pts: • CSF leak. • Wound infection requiring washout. • DVT. • -Hardware failure requiring revision. • Another wound infection requires a washout.	None
15.	Eichberg (2018) <sup>[39]</sup>	10	2 conus medullaris syndrome 4 paraparesis 4 myelopathy 1 bilateral foot drop	8 embolization 3 ethanol injections	7 STR 2 GTR 1 <i>En-bloc</i>	26 months	2 post-operative lower extremity weaknesses, both of which resolved spontaneously.	1
16.	Fox and Onofrio (1993) <sup>[11]</sup>	11	13 back/neck pain 11 progressive neurological deficit+cord compression	2	STR ± adjuvant RT	8.7 years	1 excessive intraoperative bleeding. 1 epidural hematoma requiring evacuation. Residual neurological deficits	2 no RT group 1 RT group
18.	Singh, <i>et al.</i> (2011) <sup>[40]</sup>	10	4 paraplegia 6 paraparesis	None	DC+Fusion+ethanol injection	12-26 months	None	None
19.	Pastushyn <i>et al.</i> (1998) <sup>[11]</sup>	86	Back pain ± neurological deficit	None	64 laminectomies	6-180 months	4 deaths	16

No.: Number, Pts: Patients, DC: Decompression, VP: Vertebroplasty, SCL: Sclerotherapy, AGSi: Absorbable gelatin sponge injection, AA: Anterior approach, PA: Post-approach, STR: Subtotal resection, GTR: Gross total resection, RT: Radiotherapy, Fx: Fracture.



circumferential instrumentation and fusion, to minimize the risk of recurrence. Ten patients with Enneking SIII lesions underwent aggressive intralesional spondylectomy, cage reconstruction, and instrumentation in that case series. No recurrence was reported during the 2.4-year average follow-up period.<sup>[29]</sup> In a large multicenter cohort study, Goldstein *et al.*<sup>[25]</sup> reported that in patients with aggressive radiological appearance of symptomatic VH, aggressive intralesional resection during index surgery was associated with an excellent survival rate and minimal recurrence (3%). They concluded that a total *en bloc* spondylectomy (TES) to achieve a wide resection margin is unnecessary since it is associated with surgical morbidity and massive intraoperative blood loss.<sup>[25]</sup> All patients were treated with intralesional spondylectomy in the present case series, and no recurrence was reported in their final follow-up [Figures 6 and 7].

Ji *et al.* reported good results with TES in patients with aggressive hemangiomas. In their case series, 23 patients were treated with TES; complications were minimal, and no recurrence was reported.<sup>[33]</sup> Similarly, Kato *et al.* performed a combination of preoperative transarterial embolization and total excision in five patients with AVH and spinal cord compression. Their long follow-up results were satisfactory, with no recurrence.<sup>[34]</sup>

Radiotherapy may reduce the recurrence rate in case of partial resection. None of the patients in this study underwent postoperative radiotherapy due to the risk of radiotherapy-associated complications such as radionecrosis, radiation-induced myelitis, and malignancy.<sup>[14]</sup> Fox and Onofrio reported recurrence in two out of four cases that were treated without adjuvant radiotherapy.<sup>[1]</sup> Jiang *et al.* proposed radiotherapy in cases of partial tumor excision and where intraoperative cement filled the lesion defect with no remnant epidural mass.<sup>[35]</sup> Dang *et al.* suggested that there was no need for adjuvant radiotherapy in patients who undergo intraoperative vertebroplasty of alcohol injection. Radiotherapy is indicated when a residual lesion is seen on contrast-enhanced computed tomography.<sup>[14]</sup>

The following complications were observed in our case series. One patient developed postoperative pulmonary embolism that was treated medically with anticoagulants. Another patient had an intraoperative incidental durotomy, which was successfully repaired. Distal junctional kyphosis was noted in one patient during follow-up and is being managed conservatively. Reported complications were not directly related to the treatment of AVHs and were commonly observed in other spinal surgeries.

We appreciate that our cohort was limited by the retrospective nature and the small number of patients. Therefore, we recommend a prospective study that explores treatment options with a larger number of patients. This is the first cohort conducted in two centers in Saudi Arabia to the best of our knowledge.

## CONCLUSION

Several surgical treatment options are available for patients with Enneking SIII VHs. We find intralesional spondylectomy to be an excellent surgical technique; all our 11 patients had excellent results and complete neurological recovery. However, further research is required to investigate various surgical techniques and their associated complications and recurrence rates.

## AUTHORS' CONTRIBUTIONS

FK conceived and designed the study, AB, ABS, and AA conducted research, provided research materials, and collected and organized the data. MA, MA, FA, and SA analyzed and interpreted data. All authors have critically reviewed and approved the final draft and are responsible for the manuscript's content and similarity index.

## ETHICAL APPROVAL

IRB approval was obtained on 4 June 2020 from KAIMRC with reference number IRBC/0779/20.

## Declaration of patient consent

The authors certify that they have obtained all appropriate patients consent forms for the study. In the form, the patients have given their consent for their images and other clinical information to be reported in the journal. The patients understand that their names and initials will not be published and due efforts will be made to conceal their identity, but anonymity cannot be guaranteed.

## Financial support and sponsorship

This study did not receive any specific grant from funding agencies in the public, commercial, or not-for-profit sectors.

## Conflicts of interest

There are no conflicts of interest.

## REFERENCES

1. Fox MW, Onofrio BM. The natural history and management of symptomatic and asymptomatic vertebral hemangiomas. *J Neurosurg* 1993;78:36-45.
2. Hu W, Kan SL, Xu HB, Cao ZG, Zhang XL, Zhu RS. Thoracic aggressive vertebral hemangioma with the neurologic deficit: A retrospective cohort study. *Medicine (Baltimore)* 2018;97:e12775.
3. McEvoy SH, Farrell M, Brett F, Looby S. Haemangioma, an uncommon cause of an extradural or intradural extramedullary mass: Case series with radiological pathological correlation. *Insights Imaging* 2016;7:87-98.

4. Unni KK, Ivins JC, Beabout JW, Dahlin DC. Hemangioma, hemangiopericytoma, and hemangioendothelioma (angiosarcoma) of bone. *Cancer* 1971;27:1403-14.
5. Tekkök IH, Açıgöz B, Sağlam S, Önel B. Vertebral hemangioma symptomatic during pregnancy-report of a case and review of the literature. *Neurosurgery* 1993;32:302-6.
6. Laredo JD, Reizine D, Bard M, Merland JJ. Vertebral hemangiomas: Radiologic evaluation. *Radiology* 1986;161:183-9.
7. Dobran M, Mancini F, Nasi D, Gladi M, Sisti S, Scerrati M. Surgical treatment of aggressive vertebral hemangioma causing progressive paraparesis. *Ann Med Surg (Lond)* 2017;25:17-20.
8. Fechner R, Mills S. Vascular lesions. In: *Tumors of the Bones and Joints Third Series Fascicle. Vol. 8.* Washington, DC: Armed Forces Institute of Pathology; 1993. p. 129-44.
9. Xu W, Lan Z, Huang Y. Intraoperative injection of absorbable gelatin sponge (AGS) mixed with cement followed by spinal decompression to treat elderly with vertebral hemangiomas. *BMC Musculoskelet Disord.* 2020;21:125.
10. Chen HI, Heuer GG, Zaghoul K, Simon SL, Weigele JB, Grady MS. Lumbar vertebral hemangioma presenting with the acute onset of neurological symptoms. *J Neurosurg Spine* 2007;7:80-5.
11. Pastushyn AI, Slin'ko EI, Mirzoyeva GM. Vertebral hemangiomas: Diagnosis, management, natural history and clinicopathological correlates in 86 patients. *Surg Neurol* 1998;50:535-47.
12. Aich RK, Deb AR, Banerjee A, Karim R, Gupta P. Symptomatic vertebral hemangioma: Treatment with radiotherapy. *J Cancer Res Ther* 2010;6:199.
13. Enneking WF. A system of staging musculoskeletal neoplasms. *Clin Orthop Relat Res* 1986;204:9-24.
14. Dang L, Liu C, Yang SM, Jiang L, Liu ZJ, Liu XG, *et al.* Aggressive vertebral hemangioma of the thoracic spine without typical radiological appearance. *Eur Spine J* 2012;21:1994-9.
15. Goyal M, Mishra NK, Sharma A, Gaikwad SB, Mohanty B, Sharma S. Alcohol ablation of symptomatic vertebral hemangiomas. *Am J Neuroradiol* 1999;20:1091-6.
16. Kriz J, Seegenschmiedt HM, Bartels A, Micke O, Muecke R, Schaefer U, *et al.* Updated strategies in the treatment of benign diseases-a patterns of care study of the german cooperative group on benign diseases. *Adv Radiat Oncol* 2018;3:240-4.
17. Nair AP, Kumar R, Srivastav AK, Sahu RN, Kumar B. Outcome of dorsolumbar vertebral hemangiomas presenting with neuraxial compression. *Indian J Orthop* 2012;46:536-41.
18. Wang B, Meng N, Zhuang H, Han S, Yang S, Jiang L, *et al.* The role of radiotherapy and surgery in the management of aggressive vertebral hemangioma: A retrospective study of 20 patients. *Med Sci Monit* 2018;24:6840-50.
19. Acosta FL Jr., Sanai N, Chi JH, Dowd CF, Chin C, Tihan T, Chou D, *et al.* Comprehensive management of symptomatic and aggressive vertebral hemangiomas. *Neurosurg Clin N Am* 2008;19:17-29.
20. Friedman DP. Symptomatic vertebral hemangiomas: MR findings. *Am J Roentgenol* 1996;167:359-64.
21. Gaudino S, Martucci M, Colantonio R, Lozupone E, Visconti E, Leone A, *et al.* A systematic approach to vertebral hemangioma. *Skeletal Radiol* 2014;44:25-36.
22. Huang Y, Xu W, Chen Q, Lan Z. Treatment of typical enneking stage 3 thoracic aggressive vertebral hemangiomas with pain and neurologic deficits: Results after at least 36 months of follow-up. *World Neurosurg* 2020;134:e642-8.
23. Jiang H. Comparing pain reduction following vertebroplasty and conservative treatment for osteoporotic vertebral compression fractures: A meta-analysis of randomized controlled trials. *Pain Physician* 2013;16:455-64.
24. Lis E, Bilsly MH, Pisinski L, Boland P, Healey JH, O'malley B, *et al.* Percutaneous CT-guided biopsy of osseous lesion of the spine in patients with known or suspected malignancy. *AJNR Am J Neuroradiol* 2004;25:1583-8.
25. Goldstein CL, Varga PP, Gokaslan ZL, Boriani S, Luzzati A, Rhines L, *et al.* Spinal hemangiomas: Results of surgical management for local recurrence and mortality in a multicenter study. *Spine (Phila Pa 1976)* 2015;40:656-64.
26. Chen YL, Hu XD, Xu NJ, Jiang WY, Ma WH. Surgical treatment of compressive spinal hemangioma: A case series of three patients and literature review. *Orthopäde* 2017;47:221-7.
27. Hekster RE, Luyendijk W, Tan TI. Spinal-cord compression is caused by vertebral haemangioma relieved by percutaneous catheter embolisation. *Neuroradiology* 1972;3:160-4.
28. Robinson Y, Sheta R, Salci K, Willander J. Blood loss in surgery for aggressive vertebral haemangioma with and without embolisation. *Asian Spine J* 2015;9:483-91.
29. Acosta FL, Sanai N, Cloyd J, Deviren V, Chou D, Ames CP. Treatment of enneking stage 3 aggressive vertebral hemangiomas with intralesional spondylectomy: Report of 10 cases and review of the literature. *J Spinal Disord Tech* 2011;24:268-75.
30. Wang B, Han SB, Jiang L, Liu XG, Yang SM, Meng N, *et al.* Intraoperative vertebroplasty during surgical decompression and instrumentation for aggressive vertebral hemangiomas: A retrospective study of 39 patients and review of the literature. *Spine J* 2018;18:1128-35.
31. Zhang H, Zhao S, Zhao Z, Tang L, Guo Q, Liu S, *et al.* The association of rs1149048 polymorphism in *Matrilin-1*(MATN1) gene with adolescent idiopathic scoliosis susceptibility: A meta-analysis. *Mol Biol Rep* 2014;41:2543-9.
32. Corniola MV, Schonauer C, Bernava G, Machi P, Yilmaz H, Lemée JM, *et al.* Thoracic aggressive vertebral hemangiomas: Multidisciplinary management in a hybrid room. *Eur Spine J* 2020;29:3179-86.
33. Ji X, Wang S, Oner FC, Bird JE, Lu N. Surgical management of enneking stage 3 aggressive vertebral hemangiomas with neurological deficit by one-stage posterior total en bloc spondylectomy. *Spine (Phila Pa 1976)* 2020;45:E67-75.
34. Kato S, Kawahara N, Murakami H, Demura S, Yoshioka K, Okayama T, *et al.* Surgical management of aggressive vertebral hemangiomas causing spinal cord compression: Long-term clinical follow-up of five cases. *J Orthop Sci* 2010;15:350-6.
35. Jiang L, Liu XG, Yuan HS, Yang SM, Li J, Wei F, *et al.* Diagnosis and treatment of vertebral hemangiomas with the neurologic deficit: A report of 29 cases and literature review. *Spine J* 2014;14:944-54.
36. Vasudeva VS, Chi JH, Groff MW. Surgical treatment of aggressive vertebral hemangiomas. *Neurosurg Focus* 2016;41:E7.
37. Prabhuraj AR, Mishra A, Mishra RK, Pruthi N, Saini J,

- Arvinda HR. Per-operative glue embolization with surgical decompression: A multimodality treatment for aggressive vertebral haemangioma. *Interv Neuroradiol* 2019;25:570-8.
38. Girardo M, Zenga F, Bruno LL, Rava A, Massè A, Maule M, *et al.* Treatment of aggressive vertebral hemangiomas with poly vinyl alcohol (PVA) microparticles embolization, PMMA, and short segment stabilization: Preliminary results with at least 5 years of follow-up. *World Neurosurg* 2019;128:e283-8.
39. Eichberg DG, Starke RM, Levi AD. Combined surgical and endovascular approach for treatment of aggressive vertebral haemangiomas. *Br J Neurosurg* 2018;32:381-8.
40. Singh P, Mishra NK, Dash HH, Thyalling RK, Sharma BS, Sarkar C, *et al.* Treatment of vertebral hemangiomas with absolute alcohol (ethanol) embolization, cord decompression, and single level instrumentation: A pilot study. *Neurosurgery* 2011;68:78-84.