

*Case Report*

Postmeniscectomy osteonecrosis of the knee: A case report and literature review

Abdulaziz Z Alomar, MSc., FRCSC.

Department of Orthopedic, King Saud University Medical city, College of Medicine, King Saud University, Riyadh, Saudi Arabia.

***Corresponding author:**Abdulaziz Z Alomar,
Head, Arthroscopy and Sports
Medicine division, King Saud
University Medical city,
College of Medicine,
King Saud University,
Riyadh, Saudi Arabia

dr_abdulaziz@yahoo.com

Received : 13 Mar 2021

Accepted : 12 May 2021

EPub Ahead of Print: 22 Jun 2021

Published : 13 November 2021

DOI

10.25259/JMSR_44_2021

Quick Response Code:**ABSTRACT**

Postarthroscopic osteonecrosis of the knee (PAONK) is a rare form of osteonecrosis for which the pathogenesis and etiology remain poorly understood; however, there is evidence of a close association with meniscectomy in most PAONK cases. Based on this evidence, postmeniscectomy osteonecrosis of the knee (PMONK) has been suggested as a new category. As early diagnosis and appropriate treatment can improve prognosis, there is a need to differentiate PMONK from spontaneous osteonecrosis of the knee (SONK). This differentiation is specifically important in the Middle East and Arab countries where PMONK and PAONK have not been reported before, which could have resulted from under-reporting or under-diagnosis. To address this gap, we present a case of PMONK from this region and discuss assessment findings and treatment relative to the current evidence.

Keywords: Arthroscopy, Avascular necrosis, Meniscectomy, Osteonecrosis, Osteoarthritis**INTRODUCTION**

Osteonecrosis of the knee is the development of an ischemic lesion generally on the weight-bearing surface of the medial femoral condyle.^[1] Osteonecrosis lesions are classified as spontaneous, secondary, or postarthroscopic osteonecrosis of the knee (PAONK), the latter including postmeniscectomy osteonecrosis of the knee (PMONK) and osteonecrosis of the postoperative knee.^[2,3] PMONK has a low incidence of reporting and diagnosis in Middle East and Arab countries, reflecting the overall low incidence of PMONK.^[4,5] We do know that the likelihood of PMONK is higher for medial than lateral meniscal tears, with the medial femoral condyle being more frequently involved (82% of cases), compared to the lateral femoral condyle (8.5%) and the lateral (2.1%) and medial (2.1%) tibial plateaus.^[3]

We present a case of PMONK from the Middle East and Arab region and discuss our findings within the context of current evidence.

CASE REPORT

A 69-year-old man had a 3-month history of medial right knee pain that increased with activities involving knee flexion, being most severe with deep knee bending. There was no history of significant trauma to his right knee, and his medical history was unremarkable. Non-steroidal anti-inflammatory drugs (NSAIDs) provided little pain relief.

How to cite this article: Alomar A. Postmeniscectomy osteonecrosis of the knee: A case report and literature review. J Musculoskelet Surg Res 2021;5:289-93.

On examination, the patient was obese, with a body mass index of 31 kg/m². He had a normal gait pattern, with a full range of motion of the knee joint bilaterally, and no lower extremity muscle weakness. There were no signs of right knee effusion or indication of infection, and ligament stress tests were negative. A mild genu varus alignment was observed bilaterally. On palpation, there was significant tenderness along the medial aspect of the right knee. Radiographs revealed early mild arthritic changes, with mild bilateral narrowing of the medial joint space [Figure 1]. Magnetic resonance imaging (MRI), performed 6 months after symptom onset, revealed a degenerative tear of the medial meniscus, with intact cartilage and no sign of osteonecrosis [Figure 2]. Conservative management was recommended, including weight loss, activity modifications, continued use of NSAIDs, and physical therapy.

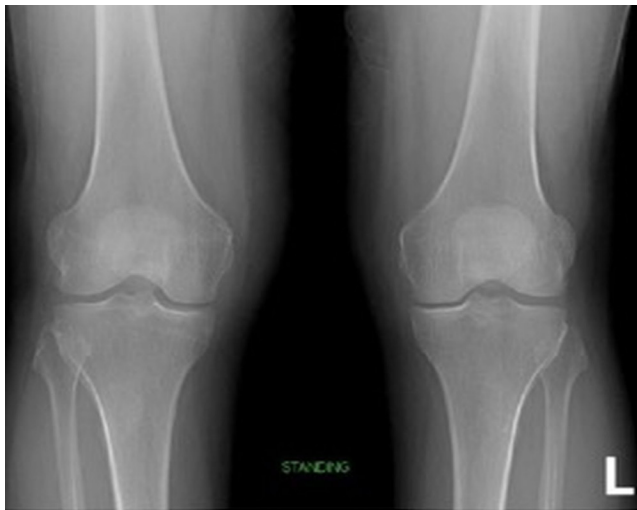

Figure 1: Preoperative standing radiograph showing mild arthritic changes of the knee joint.

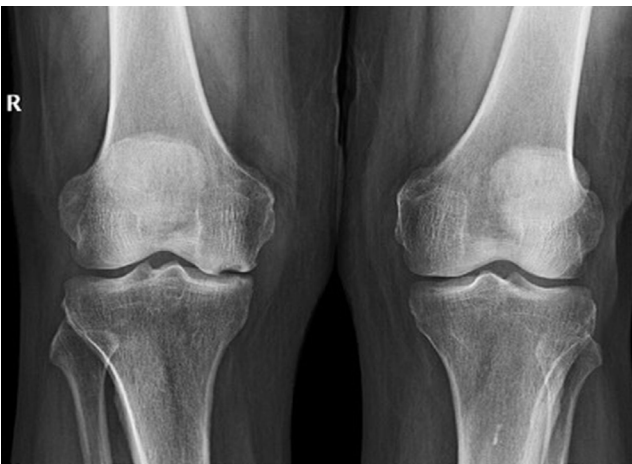

Figure 3: A standing anteroposterior radiograph showing a radiolucent lesion of the medial femoral condyle with a significant bony depression (crescent sign).

The patient underwent arthroscopic partial medial meniscectomy at another institution in Europe. He returned to our clinic 6 months later due to worsening pain over the previous 3 months. He now reported the pain in the medial knee compartment as sharp and of greater severity than preoperatively, which significantly limited his activities of daily living and required a gait aid. On examination, there was no sign of surgical wound infection. Radiographs revealed a radiolucent cortical bone depression with a rim of bony sclerosis on the medial femoral condyle [Figure 3]. A repeat MRI (6 months after surgery) confirmed the presence of bone marrow edema, associated with irregularity of the articular surface, and an area of depression on the medial femoral condyle [Figure 4]. Conservative treatment, including NSAIDs and a course of non-weight-bearing, was attempted initially. Without improvement after

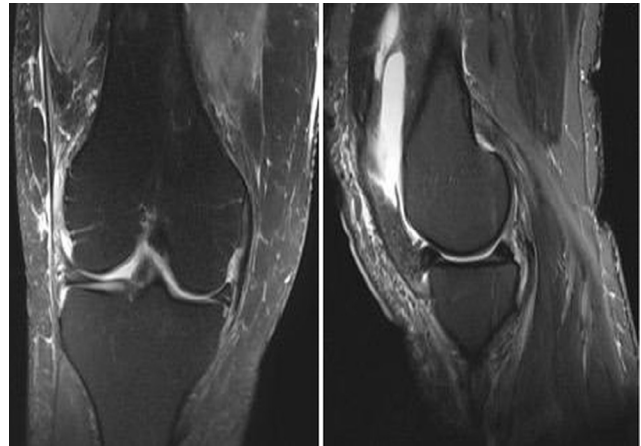


Figure 2: (a) Coronal and (b) sagittal preoperative magnetic resonance images of the right knee showing a degenerative medial meniscal tear, with no evidence of osteonecrosis.

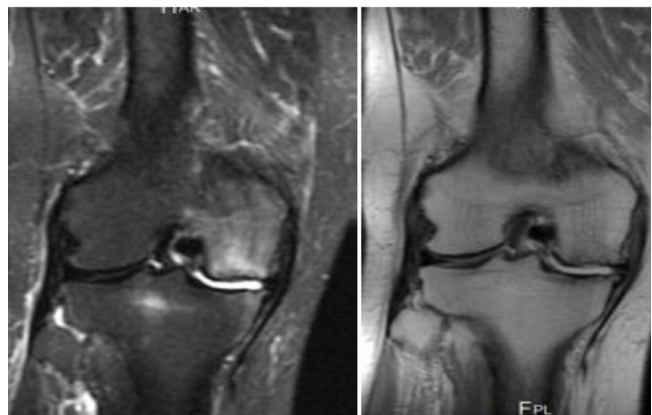

Figure 4: (a) Coronal T2- and (b) T1-weighted magnetic resonance images showing a focal subchondral patch of decreased bone marrow signal on the T1-weighted image and a high signal on the T2-weighted image of the medial femoral condyle, which indicate bone marrow edema. Irregularity of the articular surface, with a subtle depression of the articular surface and signal alteration, was observed.

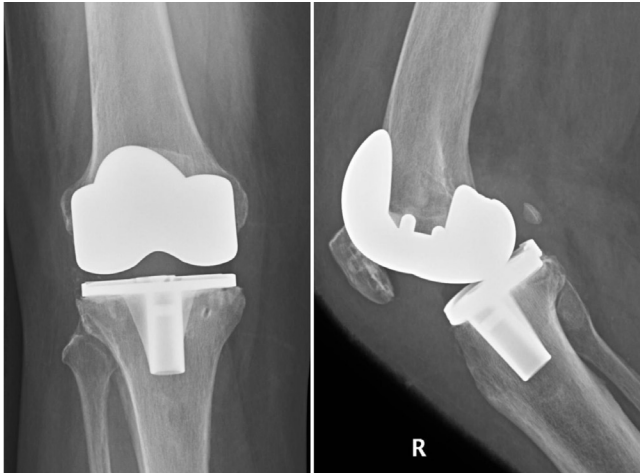


Figure 5: (a) Anteroposterior and (b) lateral radiograph showing the knee after TKA.

6 months, we proceeded with total knee arthroplasty (TKA). Intraoperatively, a contained osteochondral defect of the medial femoral condyle extending to the subchondral bone was identified. Because it was a contained and shallow lesion, it was filled with cement only [Figure 5].

DISCUSSION

To our knowledge, this is the first case of PMONK reported from the Middle East and Arab countries. It is currently unclear whether this is secondary to differences in ethnicities or if cases have been underreported.

In this case, the most likely etiology was the meniscectomy. Although the etiology of PMONK remains to be fully elucidated, meniscal tears and meniscectomy are commonly associated factors of spontaneous osteonecrosis of the knee (SONK) and PAONK, respectively.^[2,6-12] Osteonecrosis after meniscectomy may result from a change in load distribution and a resultant increase in tibiofemoral contact force, leading to fissuring and micro-fracturing of the cartilage.^[7] Hussain *et al.*^[8] identified either meniscal tears or meniscectomy in the development of osteonecrosis of the knee in > 80% of studies, recommending use of the term subchondral insufficiency fractures. Pre-existing cartilage damage or iatrogenic injury during arthroscopy may be other contributing factors allowing leakage of fluid into the subchondral bone during the procedure, which could lead to subchondral edema and, eventually, osteonecrosis.^[7,13,14]

In the current case, the diagnosis of PMONK was made based on preoperative MRI findings of intact cartilage with no sign of osteonecrosis or bone marrow edema 6 months after symptom onset. As the early stages of PMONK primarily affect the subchondral bone and bone marrow, plain radiographs have limited diagnostic value, with MRI

being the gold standard. The presence of bone marrow edema observed on preoperative MRI at 4–6 weeks after symptom onset is the main criterion differentiating spontaneous from post-meniscectomy osteonecrosis.^[15] For the diagnosis of post-meniscectomy osteonecrosis, the chronology between the meniscectomy and postoperative MRI evidence of osteonecrosis is important to consider, with a minimum of 3 months after surgery needed to detect the MRI findings of osteonecrosis owing to the large non-specific area of bone marrow edema in the femoral condyle expected immediately after surgery.^[13]

Even though the osteonecrosis size in the current case was small, the prognosis was poor and symptom progression was fast, eventually requiring TKA. Currently, there is no classification system specific to PAONK or PMONK. However, as the clinical features, radiographic findings, and the disease process are similar to those of SONK, the 5-stage radiographic classification for SONK is helpful.^[16] However, while the size of the lesion in SONK affects prognosis and treatment, the size of the PAONK lesion does not correlate with outcome.^[3] In fact, Johnson *et al.*^[6] reported rapid progression of osteonecrosis in 71% of PAONK cases, which required subsequent surgical intervention 7 months after the arthroscopy.

Currently, there are no consensus or evidence-based guidelines for PMONK treatment. Generally, conservative treatment is recommended as the first step to avoid the potential risk of accelerated joint destruction.^[15] Weight-bearing restriction for 4–8 weeks, in combination with NSAIDs and muscle strengthening, is recommended, followed by a gradual return to activities based on symptoms.^[13] However, in this case, conservative measures failed to relieve patient symptoms or stop disease progression. Therefore, conservative treatment may be less effective for PAONK than SONK, with one study reporting improvement in MRI findings after 6-week protected non-weight-bearing in only 3/47 (6.4%) cases of PAONK.^[13] Bisphosphonates, which promote bone formation by reducing the activity of osteoclasts,^[17,18] have been shown to improve pain after 4–6 weeks and completely resolved symptoms in > 50% of patients at the 6-month follow-up.^[19] In the same study, an 80% decrease in the pain score was reported with administration of intravenous pamidronate over a period of 2 weeks, followed by a weekly oral dose of alendronate for 4–6 months among 28 patients (22 PAONK and 6 SONK).^[19] The use of vasodilators, such as iloprost,^[20,21] and anticoagulants, such as enoxaparin,^[22] have been reported for the treatment of early-stage pre-collapse osteonecrosis, although further research is needed to clarify these effects. Surgical treatment is indicated for patients who do not respond well to at least 3 months of conservative management, have no clinical or radiographic

improvements, or have a lesion > 5 cm.^[16,23] Arthroscopic chondroplasty or debridement has a limited role in treating PMONK as it will not modify the natural progression of the pathology, except in cases where mechanical symptoms are present.^[13,24] High tibial osteotomy (HTO) can be considered for active young patients with a varus malalignment and early-stage disease of the medial knee compartment. HTO shifts the weight-bearing axis more laterally, offloading the medial compartment; good outcomes of HTO have been reported for cases of spontaneous osteonecrosis.^[13,25] However, the effectiveness of HTO for PMONK remains to be clarified. Similarly, core decompression has been shown to provide good outcomes for stage I and II spontaneous osteonecrosis, including successful healing in most patients with stage I lesions.^[26,27] Unicompartmental arthroplasty is a viable option for patients with a lesion isolated to a single femoral condyle or tibial plateau involvement, with no significant malalignment. TKA is advised for patients with evidence of contralateral compartment or patellofemoral joint degenerative changes.^[28] In this case, the patient had significant clinical improvement after TKA.

CONCLUSION

The incidence of PMONK has not been clearly defined in the Middle East and Arab countries. Our case indicates that PMONK does occur in these areas; thus, surgeons should be aware of this possibility. In the absence of consensus and evidence-based guidelines, treatment should be based on presenting symptoms, functional limitations, and best available evidence.

AUTHOR'S CONTRIBUTION

The author has critically reviewed and approved the final draft and is responsible for the manuscript's content and similarity index.

Declaration of patient consent

The author certifies that he has obtained all appropriate patient consent forms. In the form, the patient has given his consent for his images and other clinical information to be reported in the journal. The patient understands that his name and initials will not be published, and due efforts will be made to conceal his identity, but anonymity cannot be guaranteed.

Financial support and sponsorship

This report did not receive any specific grant from funding agencies in the public, commercial, or not-for-profit sectors.

Conflicts of interest

There are no conflicts of interest.

REFERENCES

- Ahlback S, Bauer GC, Bohne WH. Spontaneous osteonecrosis of the knee. *Arthritis Rheum* 1968;11:705–33.
- Brahme SK, Fox JM, Ferkel ED, Friedman MJ, Flannigan BD, Resnick DL. Osteonecrosis of the knee after arthroscopic surgery: diagnosis with MR imaging. *Radiology* 1991; 178:851–53.
- Pape D, Seil R, Anagnostakos K, Kohn D. Postarthroscopic osteonecrosis of the knee. *Arthroscopy* 2007;23:428–38.
- Santori N, Condello V, Adriani E, Mariani PP. Osteonecrosis after arthroscopic medial meniscectomy. *Arthroscopy* 1995;11:220–24.
- Prues-Latour V, Bonvin JC, Fritschy D. Nine cases of osteonecrosis in elderly patients following arthroscopic meniscectomy. *Knee Surg Sports Traumatol Arthrosc* 1998;6:142–47.
- Johnson TC, Evans JA, Gilley JA, Delee JC. Osteonecrosis of the knee after arthroscopic surgery for meniscal tears and chondral lesions. *Arthroscopy* 2000;16:254–61.
- Türker M, Cetik O, Cirpar M, Durusoy S, Cömert B. Postarthroscopy osteonecrosis of the knee. *Knee Surg Sports Traumatol Arthrosc* 2015;23:246–50.
- Hussain ZB, Chahla J, Mandelbaum BR, Gomoil AH, LaPrade RF. The role of meniscal tears in spontaneous osteonecrosis of the knee: a systematic review of suspected etiology and a call to revisit nomenclature. *Am J Sports Med* 2019;47:501–07.
- Muscolo DL, Costa-Paz M, Makino A, Ayerza MA. Osteonecrosis of the knee following arthroscopic meniscectomy in patients over 50 years old. *Arthroscopy* 1996;12:27–3279.
- Kobayashi Y, Kimura M, Higuchi H, Terauchi M, Shirakura K, Takagishi K. Juxta-articular bone marrow signal changes on magnetic resonance imaging following arthroscopic meniscectomy. *Arthroscopy* 2002;18:238–45.
- Schmid RB, Wirz D, Gopfert B, Arnold MP, Friederich NF, Hirschmann MT. Intra-operative femoral condylar stress during arthroscopy: an in vivo biomechanical assessment. *Knee Surg Sports Traumatol Arthrosc* 2011;19:747–52.
- Higuchi H, Kobayashi Y, Kobayashi A, Hatayama K, Kimura M. Histologic analysis of postmeniscectomy osteonecrosis. *Am J Orthop* 2013;42:220–22.
- Strauss EJ, Kang R, Bush-Joseph C, Bach Jr BR. The diagnosis and management of spontaneous and post-arthroscopy osteonecrosis of the knee. *Bull NYU Hosp Jt Dis* 2011;69: 320–30.
- DeFalco RA, Ricci AR, Balduini FC. Osteonecrosis of the knee after arthroscopic meniscectomy and chondroplasty. *Am J Sports Med* 2003;31:1013–16.
- Nakamura T, Matsumoto T, Nishino M, Tomita K, Kadoya M. Early magnetic resonance imaging and histologic findings in a model of femoral head necrosis. *Clin Orthop Relat Res* 1997;334:68–72.

16. Algietti P, Insall JN, Buzzi R. Idiopathic osteonecrosis of the knee. Aetiology, prognosis and treatment. *J Bone Joint Surg Br* 1983;65:588–97.
17. Corrado A, Quarta L, Errico S, Cantatore F. Successful treatment of avascular bone necrosis of the knee with neridronate: a case report. *Rheumatol Int* 2007;27:891–93.
18. Fromigue O, Body JJ. Bisphosphonates influence the proliferation and maturation of normal human osteoblasts. *J Endocrinol Invest* 2002;25:539–46.
19. Kraenzlin M, Graf C, Meier C, Kraenzlin C, Friedrich N. Possible beneficial effects of bisphosphonates in osteonecrosis of the knee. *Knee Surg. Sports Traumatol Arthrosc* 2010;18:1638–44.
20. Disch AC, Matziolis G, Perka C. The management of osteonecrosis-associated and idiopathic bone-marrow oedema of the proximal femur by intravenous iloprost. *J Bone Joint Surg Br* 2005;87:560–64.
21. Meizer R, Radda C, Stolz G, Kotsaris S, Petje G, Krasny C, *et al.* MRI-controlled analysis of 104 patients with painful bone marrow edema in different joint localizations treated with the prostacyclin analogue iloprost. *Wein Klin Wochenschr* 2005;117:130–35.
22. Glueck CJ, Freiberg RA, Seive L, Wang P. Enoxaparin prevents progression of stages I and II osteonecrosis of the hip. *Clin Orthop Relat Res* 2005;435:164–70.
23. Mont MA, Marker DR, Zywiell MG, Carrino JA. Osteonecrosis of the knee and related conditions. *J Am Acad Orthop Surg* 2011;19:482–94.
24. Miller GK, Maylahn DJ, Drennan DB. The treatment of idiopathic osteonecrosis of the medial femoral condyle with arthroscopic debridement. *Arthroscopy* 1986;2:21–29.
25. Koshino T. The treatment of spontaneous osteonecrosis of the knee by high tibial osteotomy with and without bone grafting or drilling of the lesion. *J Bone Joint Surg Am* 1982;64:47–58.
26. Jacobs MA, Loeb PE, Hungerford DS. Core decompression of the distal femur for avascular necrosis of the knee. *J Bone Joint Surg Br* 1989;71:583–87.
27. Forst J, Forst R, Heller KD, Adam GB. Core decompression in Ahlback's disease. Follow-up and therapy control using MR tomography. *Rofo* 1994;161:142–46.
28. Bonutti PM, Seyler TM, Delanois RE, McMahon M, McCarthy JC, Mont MA. Osteonecrosis of the knee after laser or radiofrequency-assisted arthroscopy: treatment with minimally invasive knee arthroplasty. *J Bone Joint Surg Am* 2006;88:69–75.