

**Case Report****Upper cervical spine instability due to pyogenic infection successfully treated by one stage posterior debridement and stabilization: Case Report and literature review**Faisal S. Konbaz, MD., SB-Orth¹., Sami I. Aleissa, MD., SB-Orth¹., Fahad H. Alhelal, MD., SB-Orth¹.,
Majed S. Abalkhail, MD., SB-Orth¹., Asim J. Alamri, MBBS²., Abdullah I. Saeed, MBBS¹., Asim F. Mohabbat, MBBS³.¹Department of Orthopedic Surgery, Ministry of National Guard - Health Affairs, King Abdulaziz Medical City, Riyadh, Saudi Arabia. ²Department of Orthopedic Surgery, Ministry of National Guard - Health Affairs, Prince Mohammed Bin Abdulaziz Hospital, Almadinah Almunawarah, Saudi Arabia. ³Faculty of Medicine, Taibah University, Almadinah Almunawarah, Saudi Arabia.***Corresponding author:**Asim J Alamri
Department of Orthopedic
Surgery, Ministry of National
Guard - Health Affairs, Prince
Mohammed Bin Abdulaziz
Hospital, Almadinah
Almunawarah, Saudi Arabia.

Asim8900@gmail.com

Received : 21 Mar 2021
Accepted : 11 May 2021
Epub Ahead of Print:02 Jul 2021
Published : 13 November 2021DOI
10.25259/JMSR_14_2021**Quick Response Code:****ABSTRACT**

Pyogenic osteomyelitis of the upper cervical spine is a rare condition associated with different clinical symptoms and signs. Previous studies have stressed the difficulties in making the diagnosis due to its unusual location and relatively rare occurrence. We hereby describe a case of a 65-year-old man with pyogenic infection of the craniocervical junction up to the axis with severe instability managed by posterior fusion from occiput to C6, an open biopsy from C1–C2 lesions and irrigation and debridement. On follow-up visit at two years, our patient had recovered completely. We present this case to show that the posterior approach without the anterior transoral approach is a valid surgical option in such cases. Additionally, we emphasize the importance of stabilization to successfully treat spine osteomyelitis and summarize the literature available discussing upper cervical spine infection treatment options.

Keywords: Cervical, Infection, Instability, Odontoid, Osteomyelitis**INTRODUCTION**

Pyogenic infections of the spine are generally rare, representing about 3%–4% of all bone infections. Among these, only 3%–12% are confined to the cervical spine.^[1-6] Upper cervical spine pyogenic infection is not common compared to other vertebral segment infections, and it is usually associated with unfavorable clinical outcomes.^[7] Several factors have been recognized in the literature, potentially predisposing to the development of C1–C2 osteomyelitis, including the elderly population, immunocompromised patients, and patients with associated comorbidities, such as diabetes, hypertension, and end-stage renal disease.^[6,8] Besides, upper cervical pyogenic infection diagnosis can be challenging; patients usually present with vague symptoms, and the occipitocervical pain may not be severe. High clinical suspicion is needed to reach the diagnosis.^[2] The delay in diagnosing upper cervical osteomyelitis might result in undesirable management delays, which could lead to instability and neurological deficits. The reason behind this is due to its unusual location and relatively rare occurrence. We found only 15 papers about upper cervical osteomyelitis in English literature from 1995 to 2020 [Table 1]. We hereby describe the case of a middle-aged gentleman who presented with a pyogenic infection involving the occipital condyles, the atlas and the axis with severe instability to show that the posterior approach without

How to cite this article: Konbaz FS, Aleissa SI, Alhelal FH, Abalkhail MS, Alamri AJ, Saeed AI *et al.*: Upper cervical spine instability due to pyogenic infection successfully treated by one stage posterior debridement and stabilization: case report and literature review. J Musculoskelet Surg Res 2021;5:303-11.

Table 1: Upper cervical spine pyogenic infections in the literature.

No.	Method of fixation	Complications	Outcome	Notes
1. [7]	Posterior occipito-cervical fusion	-	Complete re-ossification & fusion on follow up CT	Anterior approach was an option but due to patient condition and comorbidities, patient was managed all from posterior
2. [9]	First case: underwent two stages, 1st was posterior approach and the 2nd was anterior approach Second case: underwent also two stages, 1st was anterior approach for dens resection then posterior approach for fusion and stabilization	First case the plan initially was emergent anterior approach (C2 hemilaminectomy) but the expert surgeon was not available, so case was managed all dorsally then patient was observed for 12 days on antibiotics and still patient is symptomatic, and MRI showed no improvement.	Both patients were followed up to three years with good outcomes, MRI was the modality for follow up	First case: the decision was made to perform anterior approach after they noticed the patient did not improve clinically and radiologically Second case: the patient underwent two stages, anteriorly for dens resection and after 14 days with antibiotics and immobilization with Halo fixator placement, patient was taken to second stage which is posterior fusion and stabilization.
3. [18]	Posterior stabilization	-	X-rays performed at 12 weeks showed stability of the C1–C2 complex after the halo was removal. The patient was ambulatory with a walking stick at 6 months post-operatively	Cervical spine was immobilized postoperatively for 12 weeks in a halo fixation device
4. [19]	posterior occipitocervical arthrodesis	-	Follow-up plain radiographs and a thin cut CT demonstrated stable positioning of the instrumentation and a solid sheet of bone from the left atlantooccipital and atlantoaxial joints on the left extending to C–4.	The patient underwent a planned two-stage procedure. Stage 1 included a tracheostomy followed by a transoral transpalatal approach with adenoidectomy and debridement followed by halo vest application, then stage 2 was posterior occipitocervical arthrodesis (occiput to C–4)
5. [20]	Galli-fusion	-	The patient's neck was pain free, and she clearly demonstrated decreasing neurological symptoms in regard to tingling sensation in both hands. There was approximately a 30% reduction of the normal range of head rotation, which was expected.	-
6. [21]	Conservative	-	The patient was pain free with no neurologic deficit at the 24-month follow-up, and CT scan showed remodeling of the lesion of the atlas.	Patient was treated conservatively with 3 weeks IV antibiotics and oral 9 weeks in oral antibiotics

(Continued)

Table 1: (Contd.)

No.	Method of fixation	Complications	Outcome	Notes
7. [22]	bilateral occipital– cervical fusion from occiput	-	On examination at 3 months, 6 months, and 1 year after the surgery, patient had completely recovered with no neurologic deficit. Plain radiographs showed complete posterior fusion after 6 and 12 months, respectively.	They used bone grafts which were inserted between occiput and C1 and between the spinous processes of C2 and C3
8. [23]	Conservative	-	Follow-up evaluation 1 year after initial onset the patient had a complete relief of neck pain and there were no neurologic abnormalities, although some restriction in neck rotation remained. A CT taken at the 1-year follow-up revealed progressive bony remodeling of the left atlantoaxial joint	Patient was admitted for 15 weeks during the admission fifteen weeks was in Halo vest orthosis and 8 weeks on IV antibiotics followed by oral antibiotics for another 4 weeks.
9. [24]	laminectomy through a posterior approach	-	1st case: Three months after discharge, the muscle power in all his limbs graded 4/5. At 6 months postsurgery, his neurological examination was normal. 2nd: totally resolved of neurological symptoms	We focused in the first case as the second was lower cervical area.
10. [25]	Conservative	Progressive radiological findings (bone destruction)	Within nine months of follow up patient has progressive radiological findings, but pain was relieved as patient was immobilized within this period by external collar	Patient was treated with intravenous antibiotics for 4 weeks then oral antibiotics for 4 weeks, he was followed up with technetium 99 methylene diphosphonate bone scan and was negative
11. [26]	Two stages, the patient underwent decompression, debridement, and iliac bone grafting by the transoral mandibular tongue-splitting approach, then one week later the patient underwent posterior occipitocervical arthrodesis (-C 4) with instrumentation with halo immobilization	-incidental dural tear was detected -limited jaw mobility -superficial mucosal infections	Patient was undergoing two stages anterior then posterior approach with bone graft, they applied Halo immobilization to prevent dislocation, after two months there was no callus formation and they believed that due to radiation therapy there were no signs of dislocation	Despite this progress, the patient died of progressive nasopharyngeal carcinoma 6 months postoperatively

(Continued)

Table 1: (Contd.)

No.	Method of fixation	Complications	Outcome	Notes
12. [27]	Conservative	-	MRI that shows C2/3 spondylodiscitis and epidural abscess with cord compression (white arrow)	Patient was admitted as case of retropharyngeal abscess and MRI scan was done and revealed cervical osteomyelitis involving the second and third vertebral bodies, prevertebral and epidural abscess with spinal cord compression. Spinal stenosis in C5/6 segment was also observed, then patient was managed by six weeks of hospitalisation and combination of IV and oral antibiotics for four months
13. [28]	C1 and C2 laminectomy, irrigation, and debridement from anterior and posterior approaches	-	the patient did not regain any motor function.	On post-operative day 5, the patient and his family elected to withdraw ventilator support after consulting with palliative care of his end-of-life wishes. The patient died within 3 hours of ventilator support removal
14. [29]	Sub- occipital craniectomy, C-1 laminectomy, partial C-2 laminectomy, and cervical cord detethering with microscopic lysis of arachnoidal adhesions.	-	The patient was able to write, feed herself, and ambulate independently with a walker 12 months after surgery.	Patient had progressive neurological deficits despite conservative management for almost 3 months
15. [30]	Two stages 1st: decompression of the foramen magnum and a C1 laminectomy then 2nd: posterior fusion with iliac bone graft and halo fixation device application	Early removal of the halo fixation device was associated with recurrent neck pain and radiological evidence of atlanto-occipital subluxation. Therefore, the halo was replaced until a complete fusion developed 4 months after surgery.	Complete fusion developed 4 months after surgery.	First stage decompression of the foramen magnum and a C1 laminectomy was done then patient was observed for two months once the inflammatory markers normalized then patient underwent posterior fusion with bone graft and halo fixation device application
16. [31]	Conservative	-	During follow up, all cases were painful and limited range of movement	First case was treated by IV antibiotics 3 weeks then oral antibiotics for 36 days and Halo immobilization for 63 days and the second case was treated by IV antibiotics 24 days then oral antibiotics for 64 days and third case was treated with IV antibiotics and Halo immobilization for 44 days.

the anterior transoral approach is a valid surgical option in these cases. Additionally, we emphasize the importance of stabilization to successfully treat spine osteomyelitis and summarize the literature available discussing upper cervical spine infection treatment options.

CASE REPORT

A 65-year-old male was transferred to our hospital with severe neck pain and stiffness for two months associated with occipital pain, which affected his quality of life. He has been bedridden for two months because any movement caused excruciating neck pain. There was no history of fever, trauma, multiple joints pain, or exposure to tuberculosis or brucellosis. He was admitted to another hospital for two months, and despite doing many investigations and imaging, no clear pathology was identified. He had a positive history of diabetes, hypertension, bronchial asthma, hypothyroidism, ischemic heart disease (post angioplasty), transient ischemic attack, and old acute kidney injury requiring temporary hemodialysis.

Upon physical examination, the patient was in an acute delirium state, and in an altered general condition, confused with a Glasgow coma scale score of 13/15. His oxygen saturation was 89% on room air, catching up to 98% on 2 L/min nasal cannula, while the remaining vital signs were within normal limits. A diffuse tenderness was noted throughout the cervical spine, and the range of motion was limited due to pain. No warmth, redness, or skin changes were noticed over the cervical region. It was difficult to assess his neurological examination due to confusion, but it was grossly intact, with no upper motor neuron signs.

Laboratory studies at admission showed a white blood count (WBC) of 16.00 cells per cubic millimeter of blood, C-reactive protein (CRP) of 115 mg/dl, erythrocyte sedimentation rate (ESR) of 120 mm\hour.

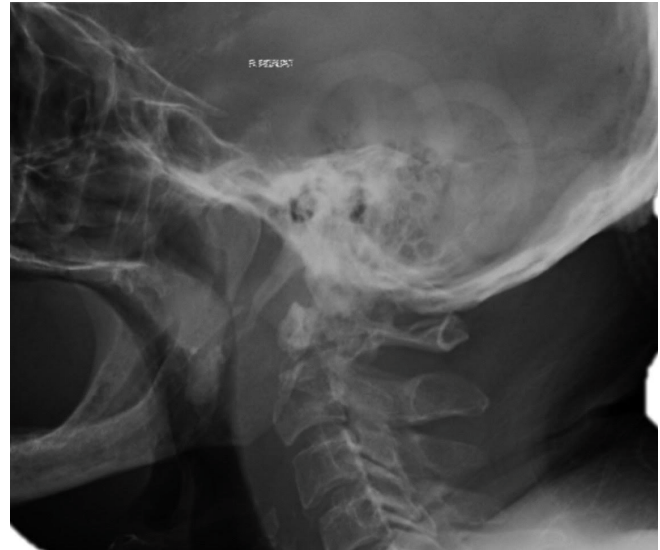

Figure 1: Cervical spine radiographs showing a destructive lesion with gross occipitocervical instability.

Tumor markers and Brucella titer were all within normal limits, and Quantiferon-TB and purified protein derivative were negative. The cervical spine radiographs showed a destructive lesion with gross occipitocervical instability [Figure 1]. A computed tomography (CT) scan demonstrated a destructive lytic lesion involving C1 and C2 with evidence of instability [Figure 2].

Gadolinium-enhanced magnetic resonance imaging (MRI) revealed mild cord compression, aggressive and destructive lesion predominately involving the body of C2, odontoid process, anterior and posterior arch of the C1 vertebra, with extra-osseous soft tissue component at the craniocervical junction and involvement of the prevertebral and paraspinal musculature [Figure 3].

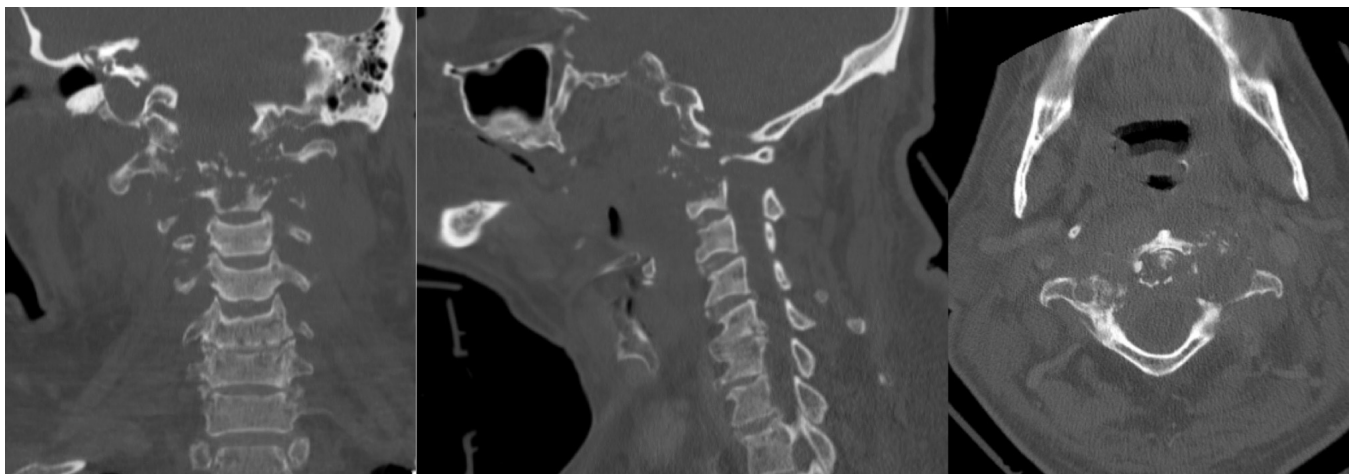


Figure 2: A computer tomography scan demonstrating destructive lytic lesion involving C1 and C2 with evidence of instability.

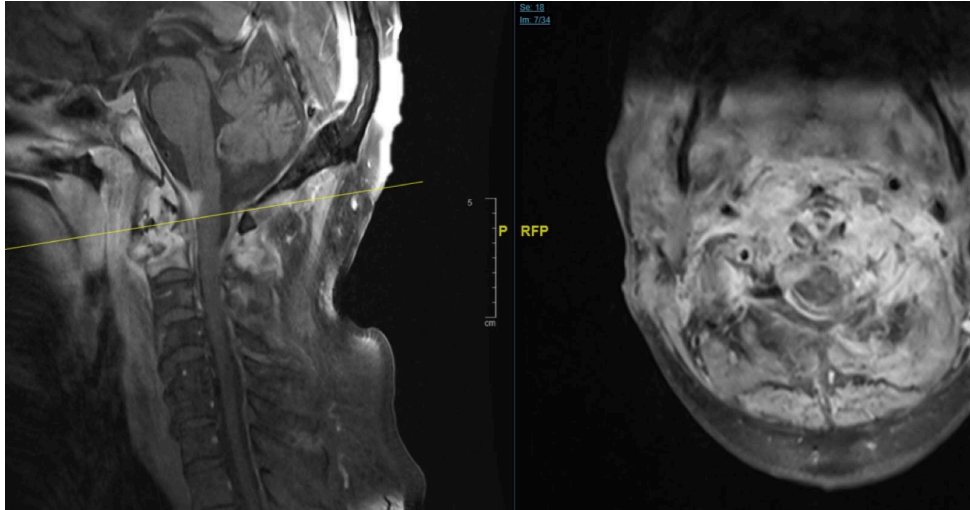


Figure 3: MRI revealed mild cord compression, aggressive, and destructive lesion predominately involving the body of C2, odontoid process, anterior and posterior arch of the C1 vertebra.

Carotid angiography CT scan showed occlusion of the 2nd segment of the left vertebral artery at the level of C1. Histological and microbiologic examinations from CT guided biopsy taken from C1–C2 paraspinal mass were all inconclusive.

The patient was scheduled to undergo a single session open biopsy from C1–C2 lesions, irrigation and debridement, and posterior cervical spine instrumentation and fusion from occiput to C6. The patient was labeled as American Society of Anesthesiologists (ASA) class 4, and he signed high-risk consent.

Surgical procedure

Under general anesthesia with endotracheal intubation, the patient was placed on Mayfield cervical management set in a prone position. Posterior cervical spine instrumentation and fusion from occiput to C6 using an intraoperative navigation system, an open biopsy from C1–C2 lesions with irrigation and debridement were performed. The left side of the C1 lateral mass was chosen to access the anterior collection based on the fact that the left vertebral artery was occluded, 5 cm³ of pus were drained. Soft tissue and bone samples were taken for histological and microbiological studies.

Bilateral C2 intralaminar screws were used due to the advanced destruction of the C2 pedicles and pars interarticularis. A third rod was added to increase the stability of the construct. At the end of the surgery, a suction drain was inserted. There were no complications during the procedure, and the patient was stable intra-operatively. Tissue, bone, and fluid samples were sent for gram stain, culture and sensitivity, TB PCR, acid-fast bacilli, TB culture, fungal culture, and histopathology.

Following the surgery, infectious disease team started the patient empirically on the following antibiotics: piperacillin/

tazobactam 4.5 g IV Q6h, vancomycin 15 mg/kg IV Q8h, rifampicin 600 mg PO once daily.

Five days later, the result of histologic and microbiologic examinations confirmed the presence of methicillin-sensitive *Staphylococcus aureus*. Vancomycin and piperacillin\ tazobactam were discontinued. The patient was started on cefazolin intravenously (2 g/6 hours) and rifampicin orally (600 mg once daily). Gradually and over the next four weeks, there was a clinical improvement; the patient was stable vitally and without neurological deficit, his confusion was completely resolved, his nutritional status improved, and he started mobilization with an extensive physiotherapy program. The antibiotic treatment was changed to a two-week oral course using cephalexin (650 mg\6 hours) and rifampicin (600 mg once daily). The patient was discharged from the hospital with a hard collar for a total of 12 weeks following the surgery. Laboratory studies at discharge showed a WBC of 5.32 cells/cm³ of blood, CRP of 12 mg/dl, ESR of 2 mm\hour. On follow-up visits at 3 and 6 months, one year and 2 years, the patient had completely recovered, with a normal WBC, CRP, ESR. Six months after surgery, the cervical spine radiographs revealed good alignment, stability, and reossification of the C1 and C2 vertebrae [Figure 4]. CT scan showed reformation of the odontoid process, bone healing of the C1 and C2 and fusion, stable positioning of the instrumentation with no signs of screw loosening [Figure 5].

DISCUSSION

In the current case, there was a two-month delay in the diagnosis despite doing many investigations, including MRI, which was inaccurately reported by the radiologist at the other hospital as degenerative changes without mentioning the infection. Consequently, when the patient presented to our clinic, there was already evidence of instability in the radiograph and CT. In the literature, we found that the delay

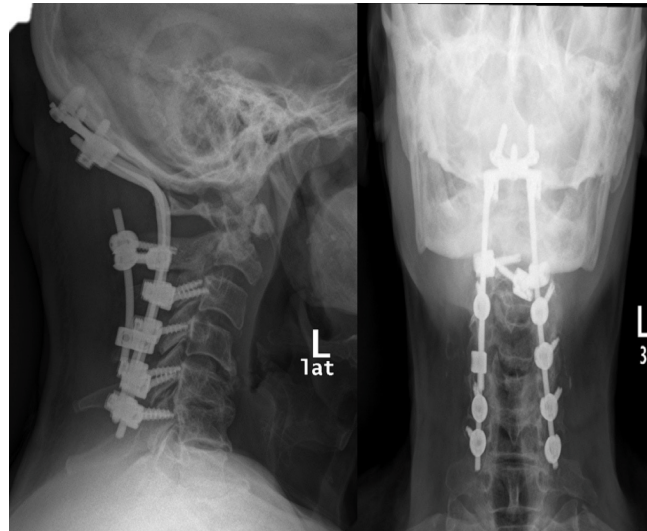


Figure 4: Radiographs showing good alignment, stability, and recalcification of C1 and C2.

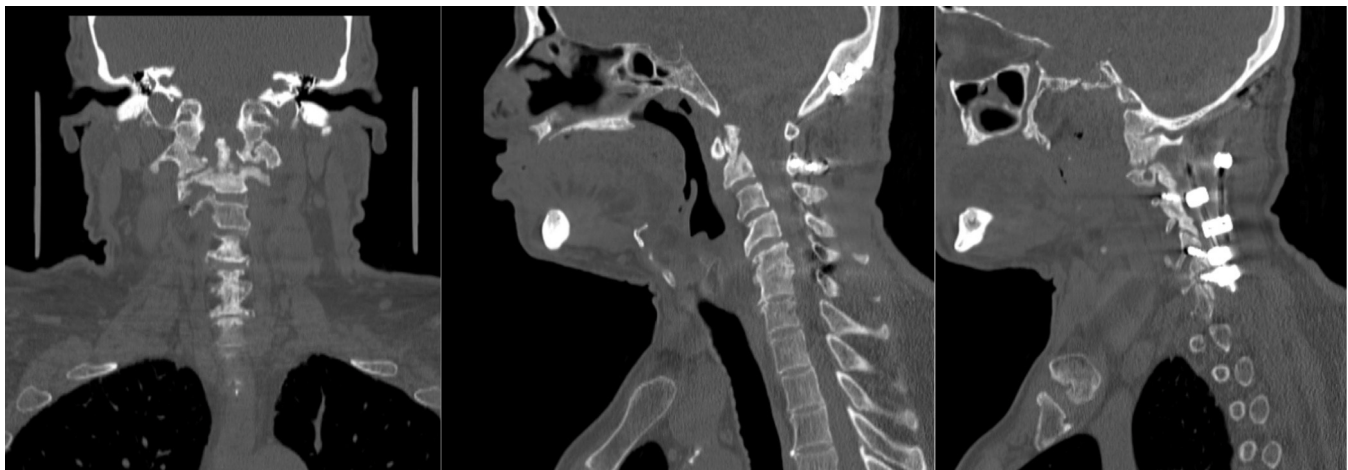

Figure 5: CT scan showed reformation of the odontoid process, bone healing of the C1 and C2 and fusion.

in diagnosis time is common. In the Schimmer *et al.* case series,^[2] two patients with C1–2 osteomyelitis were studied. The delay between the onset of symptoms and diagnosis was 5 and 8 weeks, respectively, while in Barnes *et al.* literature-based review,^[6] three publications provided data on the meantime between the onset of symptoms and diagnosis; the range was between 14.4 and 17.9 weeks.

Elevation of inflammatory markers is common in cervical spine infection and methicillin-sensitive *Staphylococcus aureus* is the most common organism.^[9] Rezai *et al.*,^[10] retrospectively reviewed 57 patients with pyogenic spinal osteomyelitis. At the time of admission, for 55 patients, ESR was 65 mm/h, two patients within a normal range, the WBC was 11, and blood cultures yielded positive results for 23 of 30 (77%) patients. The organisms from these cultures included methicillin-sensitive *Staphylococcus Aureus* in 16 cases, methicillin-resistant *Staphylococcus aureus* in 4,

Streptococcus pneumoniae in one, *Streptococcus agalacticae* in one, and *Escherichia coli* in one.

Several factors have been recognized in the literature, potentially predisposing to the development of C1–C2 osteomyelitis seen in the current case, including the age of the patient, immunocompromised status and his comorbidities.^[6,8]

Optimal management for upper cervical infection is debatable and should be adjusted according to the patient's condition, presentation time, presence of instability, and neurological deficit.

In the current case, cervical spine instability was managed by posterior fusion from occiput to C6, an open biopsy from C1–C2 lesions and irrigation and debridement. Since the organism was not identified by image-guided biopsy, besides we needed to address the cervical spine instability. We accessed the lesion through the left side C1 lateral mass

because the left vertebral artery was occluded. We were also able to take soft tissue and bone for histological and microbiological studies through this access. Furthermore, due to the advanced destruction of C1, screw insertion in its lateral masses was not feasible. So, we added a third rod to increase the stability of the construct. Similarly, due to the advanced disease involvement and destruction of the C2 pedicles and pars, the only option for C2 fixation was interlaminar screws. Bone graft was not used due to the active infection. Biomechanical studies have shown that constructs that incorporate C2 interlaminar screws provide adequate rigidity and reliable stability with comparable results to constructs utilizing C2 pedicles or pars screws.^[11,12] Intraoperative navigation was chosen to perform screw insertion and debridement for a safer procedure.^[13]

We chose a single session surgical approach to establish a histological and microbiologic diagnosis, prevent neurologic deterioration, eradicate the infection, achieve cervical spinal stability, and prompt early cervical fusion. Furthermore, since our patient had many medical comorbidities, he was not the ideal candidate for multiple anesthesia and surgeries. The anterior approach was an option, but due to many medical comorbidities and the patient's condition, we preferred to manage all from the posterior, as the anterior transoral approach would have been aggressive.

Spine fusion and instrumentation in the presence of active infection represent a dilemma to the surgeons. In the last three decades, there was an increase in the number of articles supporting spinal instrumentation in the presence of active infection.^[14,15] These articles have demonstrated that instrumentation can be used safely, and it will lead to more stability that promotes infection clearance.

Screven *et al.* believe that the spine instrumentation and fusion in the presence of active infection should be carried out urgently and without delay to prevent neurological deterioration.^[16] In a consecutive series of 32 immunocompromised patients with pyogenic vertebral osteomyelitis treated with instrumentation in an acute setting, Carragee and Iezza found a low risk of recurrence over ten years follow-up.^[17] On a follow-up visit at two years, our patient had recovered completely. CT showed complete ossification and fusion of the upper cervical spine with no signs of screw loosening.

CONCLUSION

High index of suspicion is needed to adequately diagnose upper cervical spine infections, appropriate radiological work up is indicated in a timely fashion to avoid delay in diagnosis that may result in poor prognosis and catastrophic neurological complications. Spinal stability is integral part of spine infection treatment along with identifying the organism and appropriate antibiotics treatment. Successful treatment

of upper cervical spine infection may be achieved with all posterior surgical intervention, thus avoiding the high morbidity of the upper cervical spine anterior approaches.

AUTHORS' CONTRIBUTIONS

AIS and AFM conceived and designed the study. FSK, AJA and AIS collected and organized data while FSK, SIA, FHA, MSA, and AJA wrote the initial and final draft of the article and provided critical input. All authors have critically reviewed and approved the final draft and are responsible for the content and similarity index of the manuscript.

Declaration of patient consent

The authors certify that they have obtained the patient consent form. The patient has given his consent for his images and other clinical information to be reported in the journal. The patient understands that his name and initials will not be published, and due efforts will be made to conceal his identity, but anonymity cannot be guaranteed.

Financial support and sponsorship

This report did not receive any specific grant from funding agencies in the public, commercial, or not-for-profit sectors.

Conflicts of interest

There are no conflicts of interest.

REFERENCES

1. Zigler JE, Bohlman HH, Robinson RA, Riley LH, Dodge LD. Pyogenic osteomyelitis of the occiput, the atlas, and the axis. A report of five cases. *J Bone Joint Surg Am* 1987;69:1069–73.
2. Schimmer RC, Jeanneret C, Nunley PD, Jeanneret B. Osteomyelitis of the cervical spine: a potentially dramatic disease. *J Spinal Disord Tech* 2002;15:110–7.
3. Belzunegui J, Del Val N, Intxausti JJ, De Dios JR, Queiro R, González C, Rodríguez-Valverde V, Figueroa M. Vertebral osteomyelitis in northern Spain. Report of 62 cases. *Clin Exp Rheumatol* 1999;17:447–52.
4. Dimar JR, Carreon LY, Glassman SD, Campbell MJ, Hartman MJ, Johnson JR. Treatment of pyogenic vertebral osteomyelitis with anterior debridement and fusion followed by delayed posterior spinal fusion. *Spine (Phila Pa 1976)* 2004;29:326–32; discussion 332.
5. McHenry MC, Easley KA, Locker GA. Vertebral osteomyelitis: long-term outcome for 253 patients from 7 Cleveland-area hospitals. *Clin Infect Dis* 2002;34:1342–50.
6. Barnes B, Alexander JT, Branch CL Jr. Cervical osteomyelitis: a brief review. *Neurosurg Focus* 2004;17:E11.
7. Urrutia J, Zamora T, Campos M. Cervical pyogenic spinal infections: are they more severe diseases than infections in other vertebral locations? *Eur Spine J* 2013;22:2815–20.
8. Acosta FL Jr, Chin CT, Quiñones-Hinojosa A, Ames CP, Weinstein PR, Chou D. Diagnosis and management of adult

- pyogenic osteomyelitis of the cervical spine. *Neurosurg Focus* 2004;17:E2.
9. Wiedau-Pazos M, Curio G, Grüsser C. Epidural abscess of the cervical spine with osteomyelitis of the odontoid process. *Spine (Phila Pa 1976)* 1999;24:133–36.
 10. Rezai AR, Woo HH, Errico TJ, Cooper PR. Contemporary management of spinal osteomyelitis. *Neurosurg* 1999;44:1018–25; discussion 1025–6.
 11. Gorek J, Acaroglu E, Berven S, Yousef A, Puttlitz CM. Constructs incorporating intralaminar C2 screws provide rigid stability for atlantoaxial fixation. *Spine (Phila Pa 1976)* 2005;30:1513–8.
 12. Lehman RA Jr, Dmitriev AE, Helgeson MD, Sasso RC, Kuklo TR, Riew KD. Salvage of C2 pedicle and pars screws using the intralaminar technique: a biomechanical analysis. *Spine (Phila Pa 1976)* 2008;33:960–5.
 13. Ishikawa Y, Kanemura T, Yoshida G, Matsumoto A, Ito Z, Tauchi R, et al. Intraoperative, full-rotation, three-dimensional IMAGE (o-arm)-based navigation system for CERVICAL pedicle screw insertion. *J Neurosurg Spine* 2011;15:472–8.
 14. Carragee EJ. Instrumentation of the infected and unstable spine: a review of 17 cases from the thoracic and lumbar spine with pyogenic infections. *J Spinal Disord* 1997;10:317–24.
 15. Rayes M, Colen CB, Bahgat DA, Higashida T, Guthikonda M, Rengachary S, Eltahawy HA. Safety of instrumentation in patients with spinal infection. *J Neurosurg Spine* 2010;12:647–59.
 16. Screven R, Noureldine MHA, Krafft PR, Alikhani P. Expandable titanium cages in the emergent treatment of severe spinal deformity secondary to osteomyelitis: a series of three complex cases. *Asian J Neurosurg* 2020;15:397–404.
 17. Carragee E, Iezza A. Does acute placement of instrumentation in the treatment of vertebral osteomyelitis predispose to recurrent infection: long-term follow-up in immune-suppressed patients. *Spine (Phila Pa 1976)* 2008;33:2089–93.
 18. Young WF, Weaver M. Isolated pyogenic osteomyelitis of the odontoid process. *Scand J Infect Dis* 1999;31:512–5.
 19. Reid PJ, Holman PJ. Iatrogenic pyogenic osteomyelitis of C-1 and C-2 treated with transoral decompression and delayed posterior occipitocervical arthrodesis. Case report. *J Neurosurg Spine* 2007;7:664–8.
 20. Busche M, Bastian L, Riedemann NC, Brachvogel P, Rosenthal H, Krettek C. Complete osteolysis of the dens with atlantoaxial luxation caused by infection with *Staphylococcus aureus*: a case report and review of the literature. *Spine (Phila Pa 1976)* 2005;30:E369–74.
 21. Ueda Y, Kawahara N, Murakami H, Matsui T, Tomita K. Pyogenic osteomyelitis of the atlas: a case report. *Spine (Phila Pa 1976)* 2009;34:E342–5.
 22. Suchomel P, Buchvald P, Barsa P, Lukas R, Soukup T. Pyogenic osteomyelitis of the odontoid process: single stage decompression and fusion. *Spine (Phila Pa 1976)* 2003;28:E239–44.
 23. Sasaki K, Nabeshima Y, Ozaki A, Mori H, Fujii H, Sumi M, Doita M. Septic arthritis of the atlantoaxial joint: case report. *J Spinal Disord Tech* 2006;19:612–5.
 24. Yuceer N, Arda MN. Acute epidural abscess of the cervical spine caused by *staphylococcus aureus*: report of two cases. *Turkish Neurosurg* 2001;11:111–6.
 25. Lam CH, Ethier R, Pokrupa R. Conservative therapy of atlantoaxial osteomyelitis. A case report. *Spine (Phila Pa 1976)* 1996;21:1820–3.
 26. Kobayashi T, Morimoto T, Maeda K, Toda Y, Hirata H, Yoshihara T, Mawatari M. Transoral mandibular tongue-splitting approach in upper cervical epidural abscess: a case report and review of the literature. *Spine Surg Relat Res* 2020;4:178–83.
 27. Sideris G, Nikolopoulos T, Papadimitriou N. Spontaneous, non-traumatic retropharyngeal abscess complicated by spinal osteomyelitis and epidural abscess in immunocompetent adult: management and proposal pathophysiological mechanism. *Cureus* 2020;12:e9028.
 28. Al-Hourani K, Frost C, Mesfin A. Upper cervical epidural abscess in a patient with Parkinson disease: a case report and review. *Geriatr Orthop Surg Rehabil* 2015;6:328–33.
 29. Rajpal S, Chanbusarakum K, Deshmukh PR. Upper cervical myelopathy due to arachnoiditis and spinal cord tethering from adjacent C-2 osteomyelitis. Case report and review of the literature. *J Neurosurg Spine* 2007;6:64–7.
 30. Haridas A, Walsh DC, Mowle DH. Polymicrobial osteomyelitis of the odontoid process with epidural abscess: case report and review of literature. *Skull Base* 2003;13:107–11.
 31. Spies EH, Stücker R, Reichelt A. Conservative management of pyogenic osteomyelitis of the occipitocervical junction. *Spine (Phila Pa 1976)* 1999;24:818–22.