



Original Article

Pemberton's acetabuloplasty without cast application for the treatment of acetabular dysplasia in older children: A case series

Mamon K. Kremli, FRCS.¹, Fikri A. F. Ismael, FEB-Orth.¹, Reem A. Al Mohaini², Asmaa M. Kremli, MBBS.¹

¹Department of Orthopedic Surgery, Dallah Hospital, Riyadh, Saudi Arabia, ²College of Medicine, Al-Imam Muhammad Ibn Saud Islamic University, Riyadh, Saudi Arabia.

*Corresponding author:

Mamon K. Kremli,
Department of Orthopedic
Surgery, Dallah Hospital,
Riyadh, Saudi Arabia.

mkremli@hotmail.com

Received : 08 December 2021

Accepted : 27 January 2022

Published : 14 February 2022

DOI

10.25259/JMSR_156_2021

Quick Response Code:



ABSTRACT

Objectives: To study the safety and efficacy of performing Pemberton's acetabuloplasty (PA) in older children without application of post-operative cast to avoid the restriction and complications of cast in older children.

Methods: Patients who had acetabular dysplasia and underwent Pemberton's acetabuloplasty without cast during the period 1999-2021 were selected for the study. Cases were followed until radiographic healing of the osteotomy.

Results: Twenty patients (22 hips) were included in the study. Primary acetabular dysplasia was recently discovered because of pain in 10 patients; the other 10 had residual acetabular dysplasia after treatment of developmental hip dysplasia (DDH). Most patients (19 hips in 18 patients) had a PA without internal fixation and post-operative cast. Two patients had an internal fixation with a cannulated screw because of concern about compliance with non/toe-touch weight-bearing post-operatively. The mean age on the time of surgery was 10.4 years (6.5–15.5 years). The mean body weight on the day of surgery was 42.8 Kg. (30-66 Kg.). The mean post-operative follow-up was 38 months (three months – 14 years). All patients were able to walk using a walker within five days after surgery. The follow-up radiographs showed no graft collapse and no displacement of the graft or osteotomy. Correction of the acetabular dysplasia and corrected Shenton's line were confirmed on the last follow-up with no re-dislocation or re-subluxation of the hip.

Conclusion: Performing Pemberton's acetabuloplasty in older children without application of post-operative cast is efficient and safe. Complications of cast and the gross limitation it has on daily living activities and mobilization are all avoided without compromising the surgical results and healing. Care should be taken to ensure that patients and caregivers clearly understand the importance of non/toe-touch weight-bearing post-operatively and are compliant.

Keywords: Pemberton, Acetabuloplasty, Acetabular dysplasia, Older children, Without cast

INTRODUCTION

Pemberton's acetabuloplasty (PA) is an effective method for treating acetabular dysplasia, especially in older children.^[1-3] Fixation of the osteotomy is not usually necessary unless the graft is unstable.^[4,5] Postoperatively, the patient is usually put in a hip spica cast for 6 weeks to ensure healing. This does not usually cause a problem in most young children. However, in older and

How to cite this article: Kremli MK, Ismael FA, Al Mohaini RA, Kremli AM. Pemberton's acetabuloplasty without cast application for the treatment of acetabular dysplasia in older children: A case series. J Musculoskelet Surg Res 2022;6:32-6.

heavier patients, immobilization in a hip spica cast grossly affects daily activities. Mobilization, cleaning, and going to the toilet become very difficult for both patients and caregivers which increases hip spica complications. Avoiding post-operative hip spica cast is beneficial as it increases morale and makes the post-operative period much easier. Here, we report the safety and successful use of PA without a post-operative hip spica cast.

MATERIALS AND METHODS

Patients with acetabular dysplasia that had an acetabuloplasty performed by the first author in Dallah Hospital during the period from June 1999 to June 2021 were selected for the study. The pre-requisites for this procedure are a full range of motion and congruency of the hip joint with an open or just recently closing triradiate cartilage. The inclusion criteria are age above 6 years with no post-operative cast applied. Exclusion criteria are all cases that needed open reduction with acetabuloplasty (the cast was necessary postoperatively) and those who were lost at the 3-month follow-up. The study aimed to follow cases until radiographic healing of the osteotomy was evident (minimum of 3 months). Of a total number of 21 patients, one did not come at 3 months follow-up and thus was excluded from the study. Of the 20 patients included in the study, 11 were studied retrospectively from files and parents' interviews, the remaining nine whose surgery was performed from 2016 onwards were studied prospectively. Informed consent was obtained from all caregivers stating the possibility of performing the acetabuloplasty without applying cast if the graft was very stable in compliant patients, and the possibility of either internal fixation or applying a hip spica cast only if they want to avoid another surgery for removal of implants. PA was performed through the standard approach and technique.^[6] When performing the osteotomy and spreading the distal fragment, caution was taken to avoid overextending the osteotomy or overspreading the distal fragment to maintain the normal recoil. The graft was harvested from the iliac crest above the level of the osteotomy. After inserting the graft, the stability of the graft was checked with two fingers trying to move it sideways and pulling it with a towel clip or Kocher forceps. Pulling the hip down and pushing upward further assured stability of the pelvis and hip. If there was any graft instability, internal fixation with Kirschner (K) wires (or cannulated screw in overweight patients) was used to fix the graft and osteotomy. Intraoperative radiographs were taken to assess the adequacy of the acetabular correction by assessing Shenton's line and both anterior and lateral coverage.

The choice of patient and family was carefully evaluated. We ensured that both patients and families clearly understood and showed ability and willingness to comply with given

instructions, including avoiding weight-bearing or toe-touching weight-bearing only on the operated side while mobilizing with crutches or a walker frame during the initial 6 weeks postoperatively.

Patients were trained on toe-touch weight-bearing before the surgery to ensure the ability to use the crutches and a clear understanding of instructions.

On the 1st day postoperatively, a radiograph was performed, and hip gentle passive flexion/extension and abduction/adduction motion in bed was started as tolerated. Mobilization out of bed with non/toe-touch weight-bearing and a walker usually started on the 3rd post-operative day. Most patients were discharged home on the 3rd and some on the 4th postoperative day after ensuring the ability to mobilize and go to the toilet. This added 2 more days in hospital compared to patients with hip spica cast; however, we feel that this is a worthy price as the postoperative period without hip spica avoids many problems and complications to both patients and caregivers.

The first follow-up was performed 10 days postoperatively with inspection of wound and radiograph. The second follow-up took place at 6 weeks and if good healing was seen on a radiograph, partial weight-bearing was started gradually going to full weight-bearing within 12 weeks after surgery.

RESULTS

PA was performed without any post-operative casting for the treatment of acetabular dysplasia by the senior author in a total of 20 children (22 hips). All were girls. Primary acetabular dysplasia was recently discovered because of pain in 10 patients; the other 10 had residual acetabular dysplasia after the treatment of developmental hip dysplasia (DDH). Most patients (19 hips in 18 patients) had a PA without internal fixation and post-operative cast. Two patients had an internal fixation with a cannulated screw because of concern about compliance with non/toe-touch weight-bearing postoperatively. Two patients (age 9.3 and 10 years) had bilateral PA performed on both hips simultaneously without internal fixation and cast. The mean age at the time of surgery was 10.4 years (6.5–15.5 years). The mean body weight on the day of surgery was 42.8 kg (30–66 kg).

All cases were followed up until radiographic healing was evident. The mean postoperative follow-up was 38 months (3 months–14 years). Pain medications were used during the first few days more often than those held in a hip spica cast post-operatively. Initially, passive hip motion 1st day after surgery was performed after intravenous paracetamol, otherwise was too painful. After discharge, most caregivers reported the need to continue using simple oral pain killers for 5–8 days. Fourteen patients were able to walk using a walker on the 3rd postoperative day, four

on the 4th, and one on the 5th post-operative day. The two patients who had simultaneous acetabuloplasty on both hips were mobilized in a wheelchair. All acetabuloplasties formed the expected callus 6 weeks after surgery without graft displacement and healed well after 12 weeks. The follow-up radiographs showed no graft collapse and no displacement of the graft or osteotomy. Correction of the acetabular dysplasia and corrected Shenton's line was confirmed on the last follow-up with no redislocation or resubluxation of the hip.

The attached figures illustrate cases of successful PA without cast and internal fixation [Figure 1], PA combined with a femoral varus osteotomy with no post-operative cast [Figure 2], bilateral simultaneous PA without a cast [Figure 3], and PA fixed with a screw and K-wire without a post-operative cast [Figure 4].

DISCUSSION

Paul Pemberton first described the PA in 1965, an incomplete pericapsular osteotomy of the ilium that redirects the acetabular roof hinging on the triradiate cartilage.^[7] It has been recognized as an effective method for treating acetabular dysplasia, especially in older children.^[1-3,8] A bone graft is inserted to hold down the acetabular roof and is impacted firmly. When correctly

performed, the graft in PA does not require fixation because the bone recoil holds and stabilizes the graft in place.^[5,8] When the graft is not firmly impacted, it might require a K-wire fixation.^[9,10] Some authors recommend internal fixation with threaded K-wires as a routine.^[11] A hip spica is needed for 6 weeks postoperatively.^[1-4] In older children and overweight patients, the hip spica cast could become a real burden for both the patient and family, preventing mobilization and grossly limiting daily tasks and toilet privileges. This has a definite psychological and physical impact that was seen in our series of older children with an average weight of 42.8 Kg. In such patients, it is very difficult and sometimes impossible to mobilize if a hip spica cast was applied.

Furthermore, the cast has many complications, including joint stiffness, pressure sores, skin rashes, skin ulceration, and infection with a possibility to reach septic shock, transient femoral nerve palsy, and cast-saw injuries during removal.^[12-19] Superior mesenteric artery syndrome has been reported as a complication in a 10-year-old girl after hip spica application.^[20] Transportation in vehicles becomes a real burden and may become unsafe.^[21,22]

In cases of PA without open reduction, hip spica cast may be avoided postoperatively if the patients and caregivers

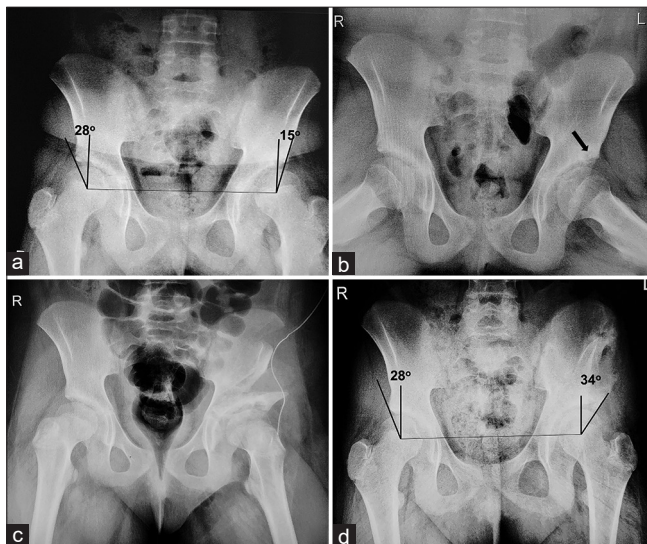


Figure 1: An 11-year-old girl who presented with left hip and thigh pain. (a) AP pelvic radiograph shows acetabular dysplasia of the left hip with superior subluxation of the femoral head and a central-edge angle of 15°. (b) AP radiograph in abduction shows a cyst (arrow) at the lateral part of the acetabulum and disrupted Shenton's lines (dotted curves) bilaterally. (c) Immediate post-operative radiograph after pemberton acetabuloplasty without cast and internal fixation shows good coverage. (d) AP radiograph 11 years after surgery shows a good acetabular cover with a central-edge angle of 34°.

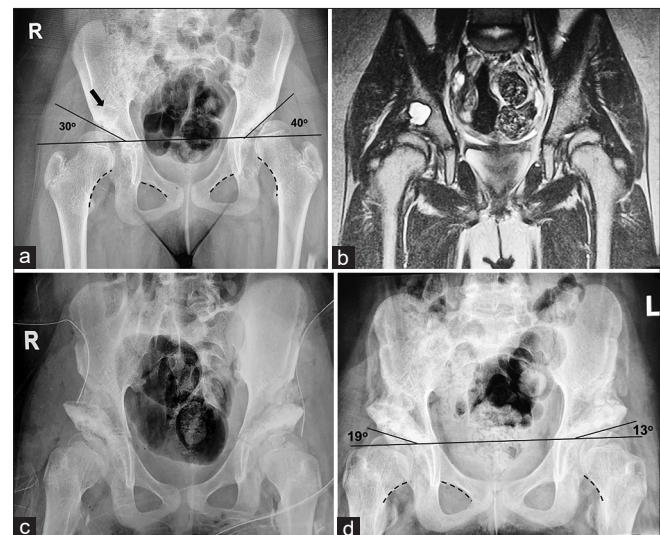


Figure 2: A 10-year-old girl presenting with pain in both hips and a bilateral positive Trendelenburg test. (a) AP standing pelvic radiograph shows bilateral acetabular dysplasia, a large cyst (arrow) above the right acetabulum with increased acetabular index and disrupted Shenton's lines (dotted curves) bilaterally. (b) MRI shows a large reactive cyst in the right acetabulum and deformed femoral heads bilaterally. (c) Immediate post-operative radiograph after bilateral pemberton acetabuloplasty without cast and internal fixation shows improved acetabular cover bilaterally. (d) AP radiograph 2 months after surgery showing healing in progress with reduced AI and improved Shenton's lines.

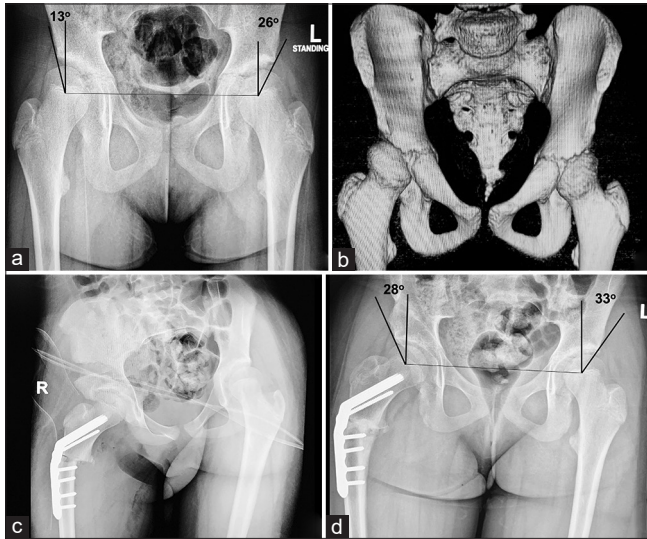


Figure 3: An 11-year-old girl who was treated for bilateral DDH by closed reduction at 6 m of age, presenting with right hip pain, limping on exertion, positive Trendelenburg test, and increased internal rotation (85°) with loss of external rotation. (a) AP standing radiograph of the pelvis shows residual right acetabular dysplasia with coxa valga of the right hip and reduced central-edge angle. (b) 3D-CT scan shows acetabular dysplasia and femoral anteversion. (c) Immediate post-operative radiograph after Pemberton acetabuloplasty and femoral varus derotation osteotomy with no cast. (d) Radiograph 6 months after surgery with good acetabular cover and normal center-edge angle.

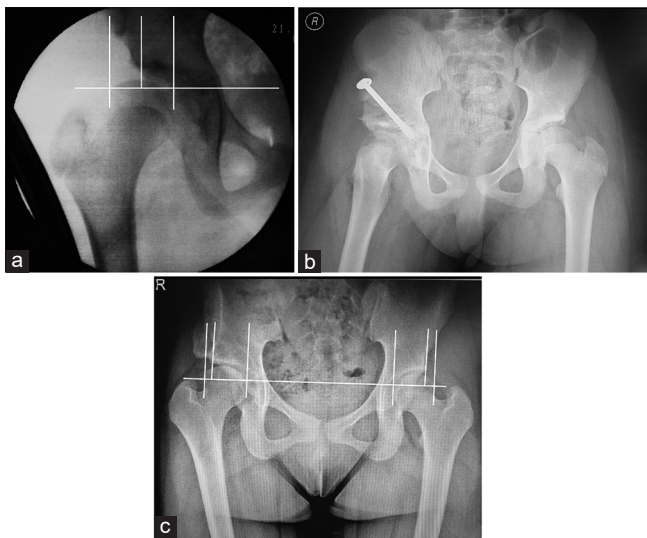


Figure 4: An 11-year-old girl who has had surgery of the right hip for DDH presented with pain and limping on the right hip. (a) Pre-operative image intensifier radiograph shows persistent acetabular dysplasia with 45% uncoverage of the femoral head. (b) Immediate post-operative radiograph after pemberton acetabuloplasty fixed with a cannulated screw without cast. (c) Fourteen years after surgery, she reports no hip pain and good hip function. Standing pelvis radiograph shows good femoral head coverage even in adduction identical to the other hip (16% uncoverage) with mild coxa magna.

understand the importance of non/toe-touch weight-bearing only on the operative site. This is better achieved with older children who are more compliant and can be taught how to avoid weight-bearing than children younger than 6 years of age. When the patient and caregivers do not clearly understand the concept of non/toe-touch weight-bearing or the surgeon feels they may not be compliant but still would like to avoid a hip spica postoperatively, they can be offered internal fixation with a cannulated screw or K-wires, necessitating another surgery for removal later. In our series, two patients (11 and 11.5 years old) could not understand the concept of toe-touch weight-bearing, and compliance was an issue. Therefore, internal fixation was chosen and approved by the caregivers who felt that this would still be a better option compared to living with a hip spica cast at this age.

Two of our patients had a short follow-up of 3 months postoperatively; however, this was enough to demonstrate healing of the osteotomies without graft displacement. As far as we know, this is the first paper demonstrating the safe use of PA without applying a hip spica cast postoperatively. One paper applied long leg cast rather than hip spica cast after different acetabuloplasties (including Pemberton's) combined with femoral shortening and derotation osteotomy for 63 patients above 10 years of age presenting with acetabular dysplasia.^[3] This enabled some hip motion postoperatively but did not allow walking as in our series.

The limitations of this study include the relatively small number of patients and is a retrospective study for 55% of our patients, all performed by one surgeon. A multicenter prospective study on a larger number of patients is recommended.

CONCLUSION

This paper demonstrates that it is safe to perform PA in children above 6 years without applying a post-operative cast. Care should be taken to ensure that patients and caregivers clearly understand the importance of non/toe-touch weight-bearing postoperatively and are trained for this preoperatively. If doubt exists regarding compliance, the usual post-operative hip spica cast should be applied, or the caregivers could be given the option of internal fixation to avoid casting. Further studies on a more extensive series of patients after Pemberton's, Dega's, San Diego, and other osteotomies would be beneficial.

ACKNOWLEDGMENT

We would like to acknowledge the advice, help, and continuous support of Dr. Salah El Fagih.

AUTHORS' CONTRIBUTIONS

MKK: Concepts, design, the definition of intellectual content, clinical studies, literature search, data acquisition, data analysis, statistical analysis, manuscript preparation, and editing. FAI: Clinical studies and data acquisition. RAA: Literature search, manuscript editing, and review. AMK: Literature search and manuscript editing. All authors have critically reviewed and approved the final draft and are responsible for the manuscript's content and similarity index.

ETHICAL APPROVAL

The study was approved by Dallah Hospital Review Board on November 27, 2021, approval number 21-11-1.

Declaration of patient consent

Patients'/caregivers' consent to publish the data and radiographs was waived by IRB as it is impossible to identify any of the patients from the data and radiographs published in the study.

Financial support and sponsorship

This study did not receive any specific grant from funding agencies in the public, commercial, or not-for-profit sectors.

Conflicts of interest

There are no conflicts of interest.

REFERENCES

- Vedantam R, Capelli AM, Schoenecker PL. Pemberton osteotomy for the treatment of developmental dysplasia of the hip in older children. *J Pediatr Orthop* 1998;18:254-8.
- Wada A, Fujii T, Takamura K, Yanagida H, Taketa M, Nakamura T. Pemberton osteotomy for developmental dysplasia of the hip in older children. *J Pediatr Orthop* 2003;23:508-13.
- Zheng P, Tang K, Lee R, Ji C, Lin G, Pan X, et al. Surgical treatment of developmental dysplasia of the hip presenting in children above 10 years. *J Orthop Sci* 2011;16:165-70.
- Azar F, Beaty J, Canale S. *Campbell's Operative Orthopaedics*. 13th ed. Philadelphia, PA: Elsevier, Mosby; 2017. p. 1142-3.
- Chen C, Wang TM, Kuo KN. Pelvic Osteotomies for Developmental Dysplasia of the Hip. *Open Access Peer-Reviewed Chapter*; 2017.
- Huang SC, Wang TM, Wu KW, Fang CF, Kuo KN. Pemberton osteotomy for acetabular dysplasia. *JBSJ Essent Surg Tech* 2011;1:e2.
- Pemberton PA. Pericapsular osteotomy of the ilium for treatment of congenital subluxation and dislocation of the hip. *J Bone Joint Surg Am* 1965;47:65-86.
- Pemberton PA. Pericapsular osteotomy of the ilium for the treatment of congenitally dislocated hips. *Clin Orthop Relat Res* 1974;98:41-54.
- de Gauzy JS. Pelvic reorientation osteotomies and acetabuloplasties in children. *Surgical technique. Orthop Traumatol* 2010;96:793-9.
- Kuo KN, Wang TM. Pemberton osteotomy (anterolateral acetabuloplasty). In: Hamdy R, Saran N, editors. *Pediatric Pelvic and Proximal Femoral Osteotomies, A Case-Based Approach*. Cham: Springer; 2018. p. 114.
- John AH. *Tachdjian's Procedures in Pediatric Orthopaedics*. Philadelphia, PA: Elsevier; 2017. p. 70.
- Gannaway JK, Hunter JR. Thermal effects of casting materials. *Clin Orthop Relat Res* 1983;181:191-5.
- Kaplan SS. Burns following application of plaster splint dressings. Report of two cases. *J Bone Joint Surg Am* 1981;63:670-2.
- Halanski MA, Halanski AD, Oza A, Vanderby R, Munoz A, Noonan KJ. Thermal injury with contemporary cast-application techniques and methods to circumvent morbidity. *J Bone Joint Surg Am* 2007;89:2369-77.
- Lavalette R, Pope MH, Dickstein H. Setting temperatures of plaster casts. The influence of technical variables. *J Bone Joint Surg Am* 1982;64:907-11.
- Shuler FD, Grisafi FN. Cast-saw burns: Evaluation of skin, cast, and blade temperatures generated during cast removal. *J Bone Joint Surg Am* 2008;90:2626-30.
- Stork NC, Lenhart RL, Nemeth BA, Noonan KJ, Halanski MA. To cast, to saw, and not to injure: Can safety strips decrease cast saw injuries? *Clin Orthop Relat Res* 2016;474:1543-52.
- Kremli M. Septic shock with skin ulceration and infection after use of a synthetic hip spica cast for treatment of congenital dislocation of the hip. *Ann Saudi Med* 2003;23:171-2.
- Pedrotti L, Bertani B, Tuvo G, Mora R, Mosconi M, de Rosa F. Transient femoral nerve palsy in spica cast treatment for developmental dysplasia of the hip. *Pediatr Med Chir* 2018;40:38-40.
- Chen SH, Chen WS, Chuang JH. Superior mesenteric artery syndrome as a complication in hip spica application for immobilization: Report of a case. *J Formos Med Assoc* 1992;91:731-3.
- Adams AJ, Johnson MA, Ryan KA, Farrell SB, Morro M, Sankar WN. Safe transportation in-spica following surgical treatment of infantile DDH: Solutions and threats. *J Pediatr Orthop* 2019;39:488-93.
- Herman MJ, Abzug JM, Krynetskiy EE, Guzzardo LV. Motor vehicle transportation in hip spica casts: Are our patients safely restrained? *J Pediatr Orthop* 2011;31:465-8.