

# Elbow Dislocation in Sports: A Narrative Review

Mohammad A. Almalki, Mohammed H. Alkhudhayri<sup>1</sup>, Ali M. Aljomah<sup>2</sup>, Nayef A. Alhinti<sup>2</sup>, Abdulmalik F. Alhumidani<sup>3</sup>, Mishary A. Alassaf<sup>3</sup>, Shaker H. Alshehri<sup>4</sup>

Reconstructive Orthopedic Department, King Fahad Medical City, <sup>1</sup>Department of Radiology, King Abdulaziz Medical City – National Guard, <sup>2</sup>Department of Radiology, King Faisal Specialist Hospital and Research Center, <sup>3</sup>Basic Medical Science Department, College of Medicine, Dar AlUloom University, Riyadh, <sup>4</sup>Department of Surgery, College of Medicine, King Khalid University, Abha, Kingdom of Saudi Arabia

## ABSTRACT

The incidence of elbow dislocations in the normal population is approximately 6/100,000; nearly half of these cases are related to sports. Twenty-six percent of elbow dislocations have associated fractures. When all types of sports-related injuries are considered, the elbow is ranked 5<sup>th</sup> among the most common body parts injured in young athletes. Around 10%–25% of these elbow injuries are dislocations. Majority of these injuries are treated conservatively. Patients are usually fit to resume their normal functions without any significant long-term impairment after treatment. However, in a small number of patients, there is accompanying damage to the anatomical structures within the elbow joint, which aggravates the situation and deserves a more aggressive therapeutic approach and closer follow-up. Proper treatment and rehabilitation should ensure the stability of the elbow and minimize subsequent dislocations. This also prevents known complications that carry significant morbidity, can affect the athlete's performance, and hinder the progression of their careers. In this review, we covered the current literature on sports-related elbow dislocations while highlighting the role of radiology in the proper management of these patients. By reviewing the available literature, we aim to help medical practitioners to better diagnose and treat this injury and prevent its complications.

**Keywords:** Athletes, elbow dislocations, elbow injuries, elbow trauma, sports injuries

## INTRODUCTION

The elbow is a relatively stable joint; however, dislocations occur frequently. In most cases, a posterior dislocation of the semilunar notch of the ulna from the distal humerus is what occur. It is considered a simple dislocation if there is no associated fracture and the injury is closed. Disruption of the elbow joint requires a significant force because of the bony structures that provide higher stability. Therefore, it is expected to have an associated bone fracture, making it a complex dislocation. Neurovascular injuries are less common in simple, posterior dislocations compared to anterior elbow dislocations, which requires much more significant force and carries much greater possibility for neurovascular injury. Immediate closed reduction of dislocated elbow is necessary to reduce complications. Recurrent elbow dislocations increase the likelihood to have a chronic joint instability, which may require operative fixation.<sup>[1]</sup>

The elbow is the second most common joint to suffer dislocations in the general adult population, and it is the most frequently occurring injury in pediatric age groups.<sup>[2,3]</sup> Nearly half of these lesions occur in sports when falling

on an extended elbow, predominantly affecting young males. Most of these injuries are treated conservatively,<sup>[2,4]</sup> and the patient can typically return to normal activities without significant long-term impairment. However, in a small percentage of cases, there might be an accompanying damage to the anatomical structures within the elbow joint, which, if present, will aggravate the situation and deserves a more aggressive therapeutic approach and closer follow-up.<sup>[4,5]</sup>

In this review, we covered the current literature on sports-related elbow dislocations highlighting the role of radiology in the proper management of these patients. The aim of this review

**Address for correspondence:** Dr. Mohammad A. Almalki, Reconstructive Orthopedic Department, King Fahad Medical City, Riyadh, Kingdom of Saudi Arabia.  
E-mail: mohammad\_malki@hotmail.com

Received : 19-10-2019  
Accepted : 25-02-2020

Revised : 21-12-2019  
Published Online : 04-04-2020

This is an open access journal, and articles are distributed under the terms of the Creative Commons Attribution-NonCommercial-ShareAlike 4.0 License, which allows others to remix, tweak, and build upon the work non-commercially, as long as appropriate credit is given and the new creations are licensed under the identical terms.

**For reprints contact:** reprints@medknow.com

**How to cite this article:** Almalki MA, Alkhudhayri MH, Aljomah AM, Alhinti NA, Alhumidani AF, Alassaf MA, *et al.* Elbow dislocation in sports: A narrative review. *J Musculoskelet Surg Res* 2020;4:124-31.

### Access this article online

Quick Response Code:



Website:  
www.journalmsr.com

DOI:  
10.4103/jmsr.jmsr\_91\_19

is to help medical practitioners to better diagnose and treat this injury and prevent its complications.

## METHOD OF LITERATURE REVIEW

A PubMed search was performed using the following keywords: *Elbow dislocation, sports injuries, elbow injuries, upper extremity injuries, sports-related injuries, elbow trauma, and joint dislocation*. A review of the search results was performed; any articles relevant to the topic, as well as associated computer links to these abstracts, were reviewed. Once the relevant manuscripts were retrieved, the references from these articles were manually searched. The review primarily included articles written in English. All available years were covered, but only those articles published in the last 15 years were included in this review.

## EPIDEMIOLOGY

Elbow dislocations' incidence in the normal population is approximately 6/100,000,<sup>[6]</sup> and the majority of these injuries are related to sports.<sup>[7]</sup> Twenty-six percent of elbow dislocations have associated fractures.<sup>[6]</sup> When all types of sports-related injuries are considered, the elbow is ranked 5<sup>th</sup> among the most common body part injuries in young athletes. Around 10%–25% of these elbow injuries are dislocations. The incidence of elbow dislocations is higher in males when all age groups are combined; however, when both genders are analyzed separately, the incidence is higher in males below the age of 30 years, whereas females with ages between 30 and 89 years have a higher incidence.<sup>[7]</sup>

Interestingly, the nondominant side is more commonly injured. The current hypothesis is that there is an instinctive defensive reflex that protects the most valuable limb in the event of a fall, and falling on an outstretched hand in a semi-flexed elbow has been found to be the most common cause of the injury (90%).<sup>[8]</sup>

## LITERATURE ON SPECIFIC SPORTS

The practice of sports is a significant cause of elbow dislocations, even though its representation over the number of total dislocations varies across studies, with rates ranging from 34.5% to as high as 75%.<sup>[6,7,9]</sup> The risk of being injured is approximately five times higher during competition than during practice.<sup>[10]</sup>

Stoneback *et al.*<sup>[7]</sup> performed a large epidemiological study that included all elbow dislocations received at emergency departments across the United States and identified that there were a total of 1066 cases that were seen in the hospitals during the study period. Excluding pediatric cases younger than 10 years of age, 44.5% of all elbow dislocations were related to sports activities. The most prevalent sports were American football, roller-skating, ice skating, skateboarding, wrestling, and basketball, in that order. Other sports in which elbow dislocations occurred were soccer, trampoline, gymnastics, volleyball, hockey, and track.

Given the gender differences in sports preferences, the pattern and distribution of injuries across sports also differ. Males dislocated elbows more frequently in American football, wrestling, and basketball, in that order. Conversely, females suffer elbow dislocations most frequently while performing gymnastics and skating activities.<sup>[7]</sup>

Dislocations among baseball players are not as common, being responsible for only 3% of the total dislocations;<sup>[7]</sup> however, this is worth mentioning given the pattern of injury. The medial collateral ligament (MCL) of the elbow joint of pitchers is put under stress due to valgus loading of the elbow during throwing. Injury to the MCL of the elbow leads to a dislocation pattern that is rare and mostly restricted to baseball and other sports that involve a similar throwing motion (such as among javelin throwers or handball players). Unlike in other sports, where the injury results from an acute event, in baseball, the injury occurs gradually by overuse. Pitchers are vulnerable to olecranon stress fractures, which are caused by the pulls in the triceps brachii on the olecranon during the throwing motion.<sup>[11]</sup>

Another study focused exclusively on a high school population and found slightly different results. For the boys included in the investigation, American football and wrestling once again represented the top sports that led to elbow dislocation; however, the latter was the most common sport this time. In American football, 66.6% of injuries occurred during tackling or while being tackled; in wrestling, takedowns caused 63.3% of dislocations. Basketball, baseball, and lacrosse all reported lower numbers. As for girls, injuries occurred in cheerleading, soccer, gymnastics, volleyball, and basketball, in the order of the number of injuries. Of importance, it must be noted that in this study that 91.3% of the injuries occurred in boys, confirming the fact that elbow dislocations are more common in males in this age group. Lastly, when sports equally represented by both genders are analyzed separately (males' and females' football, basketball, baseball, track and field, and diving and swimming), there was no significant difference in the number of injuries.<sup>[10,11]</sup>

## PATHOANATOMY

The elbow joint is composed of three individual articulations: the radiocapitellar, ulno-trochlear, and proximal radio-ulnar joints. All the three articulations are contained in the same synovium-lined capsule.<sup>[12]</sup> From the lateral side, there is the lateral collateral ligament (LCL), which is composed of two components: the lateral ulnar collateral ligament, which prevents posterolateral translation and inserts into the tubercle of the supinator crest of the ulna. The other component is the radial collateral ligament, providing support against varus stress and inserts in the annular ligament, whose function is to keep the head of the radius in contact with the radial notch of the ulna. Medially, the MCL is divided into three segments: an anterior bundle stabilizing the joint against valgus stress and a posterior bundle and a transverse ligament in the medial aspect of the joint.<sup>[13,14]</sup>

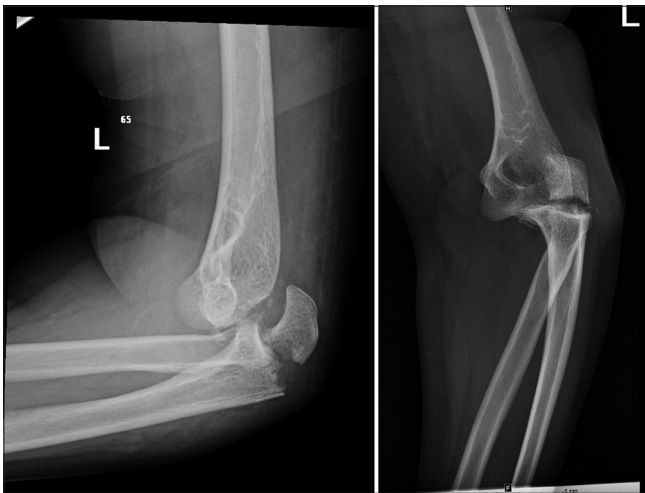Elbow dislocations can be classified into simple (without fractures) or complex when associated with one or more fractures [Figure 1].<sup>[15]</sup> They can also be classified based on the direction of the dislocation as follows: posterior [Figure 2], anterior, lateral, medial, or divergent. Almost all elbow dislocations are either posterior or posterolateral [Figure 3],<sup>[16]</sup> resulting from an injury to the LCL. If there is no associated fracture, that is the only direction in which the elbow can completely dislocate [Figure 4]. Divergent dislocations are rare because there must be a substantial injury to the anatomical structures that stabilize the joint. For this reason, they are also the most unstable injuries.<sup>[17,18]</sup>

The presently accepted mechanism of injury involves a combination of varus stress, external rotation of the forearm, and compressive axial pressure, leading to posterior elbow dislocation.<sup>[19,20]</sup> In terms of severity, O'Driscoll<sup>[21]</sup> suggested three progressive stages of soft-tissue injury that are, from lateral to medial, eventually leading to complete dislocation.

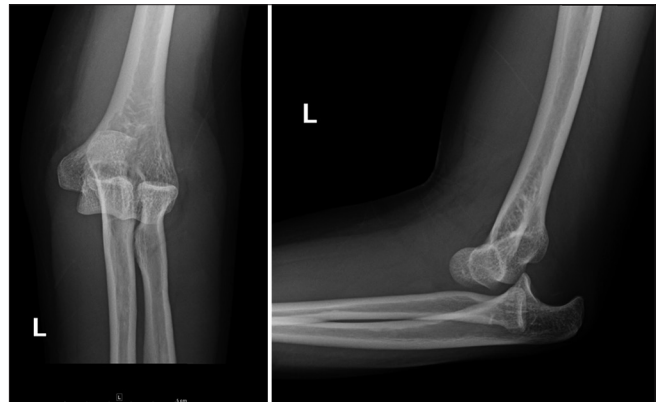
- Stage 1 – There is already some degree of posterolateral rotatory instability, but the dislocation reduces spontaneously. The only injury at this stage is a disruption of the LCL at its ulnar part. The annular ligament and radial LCL might not yet be damaged
- Stage 2 – The dislocation can still be reduced with manipulation, sometimes even accomplished by the patient himself/herself. More advanced disruption of the stabilizing components of the elbow results in a posterolateral dislocation type that is incomplete. In this case, the medial edge of the ulna rests on the trochlea
- Stage 3 – The elbow is completely dislocated at this point. The reduction is better performed by a trained physician that works with the patient, who is under general anesthesia or at least heavy sedation. Upon examination, the patient will show that the olecranon is excessively posterior to the humerus.

### CLINICAL PRESENTATION AND EXAMINATION

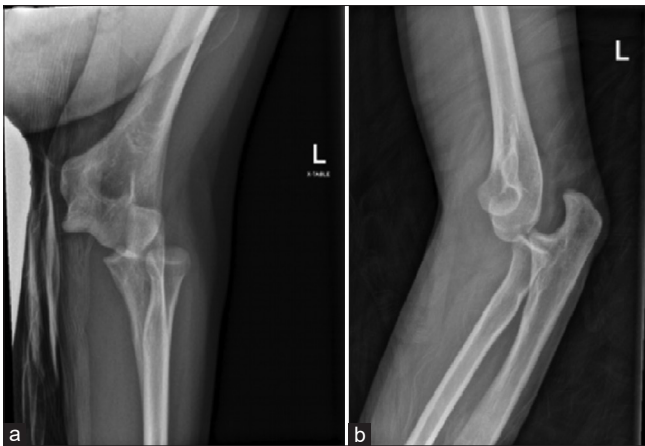
The clinical history of elbow dislocations commonly describes injuries that occur during sports activities, falling from a height, or motor vehicle accidents. Patients with suspected elbow dislocations should be questioned regarding any



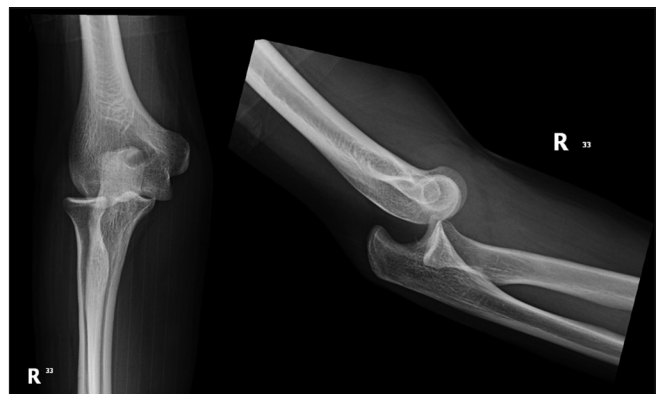**Figure 1:** X-ray of the left elbow joint showing a posterior dislocation of the left elbow joint with a displaced fracture of the olecranon process and radial head. Both fractures extend to the articular surface with multiple intra-articular bony fragments



**Figure 2:** Left elbow anteroposterior and lateral views showing a posterior elbow dislocation



**Figure 3:** (a) Anteroposterior and (b) lateral views showing posterolateral elbow dislocation



**Figure 4:** Right elbow X-ray showing a posterior elbow dislocation

symptoms of pain, numbness, paresthesia, and weakness, and they should subsequently undergo careful neurological evaluation of the local nerves to see if these are compromised. One-fifth of the elbow dislocations have an element of nerve damage. These nerve damages usually occur in either the ulnar nerve or the anterior interosseous branch of the median nerve.<sup>[22,23]</sup> In addition, the brachial artery should be assessed prior to manipulation, as it can often be injured during various reduction maneuvers.<sup>[17]</sup>

The examination should be completed by examining the joint above and the joint below and to exclude less common associated injuries. For example, assessment of the distal radial ulnar joint of the ipsilateral side and the interosseous membrane of the forearm is a must to check for disruption, which would describe a variant of the Essex–Lopresti injury.<sup>[22]</sup> Furthermore, it is normal to expect a marked swelling secondary to damage to the soft tissue, which invariably comes with dislocations of the elbow. Such swelling can lead to compartment syndrome with increased pressure within the fascial compartments of the forearm. If suspected, this swelling should be monitored closely.<sup>[21]</sup>

Following the clinical examination, the current standard of care recommends obtaining images, beginning with plain radiographs.

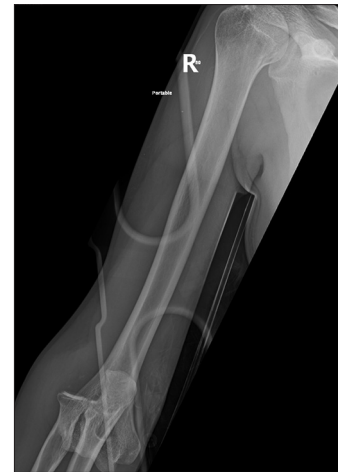## IMAGING STUDIES

### Radiography

Standard radiographic examinations should assess anteroposterior and lateral elbow views. The first images confirm the elbow dislocation, identify or rule out possible fractures, and provide information regarding the specific direction of displacement. The radiographic examination should be repeated after the dislocation is reduced; at this point, radiographs can include oblique views in order to identify any small fractures that were missed during the initial examination.<sup>[15,17,22]</sup>

The subclassification of complex elbow dislocations can only be properly done with the help of radiological examinations. Radial head fractures can be divided into four stages, depending on the extent of displacement of the radial head [Figures 5 and 6].<sup>[24]</sup> The last stage (IV) also includes dislocation of the ulno-humeral joint.<sup>[25,26]</sup> The coronoid process can also be fractured, which can be further divided into three types based on the fractured fragment's size. Fractures involving more than 50% of the coronoid process (type 3) have poorer outcomes.<sup>[27]</sup>

Special care should be taken in the diagnosis of Monteggia fracture dislocation, which is a proximal ulnar fracture with a dislocated radial head.<sup>[28]</sup> As a distinct lesion, they can also be subdivided based on the direction of the dislocation of the radial head. These fractures are treated surgically with internal fixation of the ulnar fracture, and the radial dislocations are treated conservatively with postoperative radiographs to assess any residual subluxation.<sup>[12]</sup>



**Figure 5:** X-ray of the right humerus showing right elbow dislocation with soft-tissue swelling and a focal fracture at the radial aspect of the radial head

### Computed tomography

Computed tomography (CT) is recommended when plain radiographs detect the presence of bony fragments, or if the radiologist is uncertain about the assessment and confirmation of existing fractures. CT scan and three-dimensional reconstruction are then used to assess the extent of injury better, to plan a surgical intervention, and for postoperative images [Figures 7 and 8].<sup>[15,22]</sup>

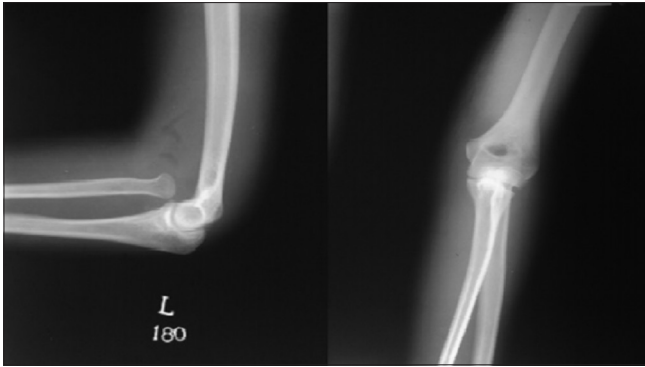
### Magnetic resonance imaging

Magnetic resonance imaging (MRI) is of limited use for the diagnosis of acute elbow dislocations, except in complex dislocations with associated fractures of the radial head, in order to evaluate the integrity of the interosseous membrane.<sup>[29]</sup> However, it can be used in cases with chronic instability (a known complication of elbow dislocation).<sup>[30]</sup> Potter *et al.*<sup>[30]</sup> were able to identify tears in the ulnar band of the LCL in all ( $n = 9$ ) symptomatic patients included in their series. Further confirming the usefulness of the MRI in those cases was the fact that all those patients had normal radiographs. Another indication for MRI examination is whenever there is a suspicion of neurovascular damage, such as in the case of the intra-articular entrapment of the median nerve following elbow dislocation.<sup>[4]</sup>

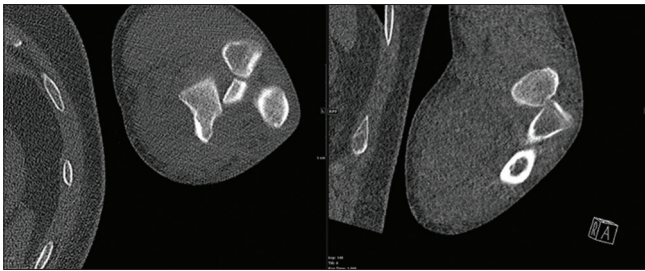
## MANAGEMENT

### Clinical

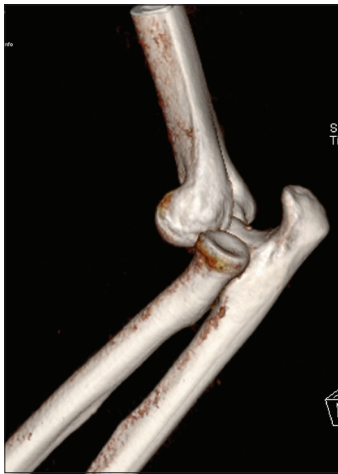Conscious sedation and muscle relaxants can help in reducing a dislocated elbow. Ideally, the patient is put into a semi-lateral position. The patient's forearm should be supinated, and the olecranon tip should be pushed firmly from a posterior distal area while doing gentle elbow flexion. Once the elbow is flexed, gentle traction longitudinally, as well as counter-traction, could help.<sup>[22]</sup> If this maneuver succeeded, the treating physician should feel a clunk and the visual appearance of the joint returns to normal; after reducing the elbow, checking the stable range of motion arc is a must. It is important to document if



**Figure 6:** Anteroposterior and lateral views showing anterior radial head dislocation



**Figure 7:** Computed tomography of the left elbow showing a posterior dislocation of the left elbow joint with complete posterior dislocation of the radial head and olecranon and intra-articular bony fragment



**Figure 8:** Computed tomography of the left elbow with three-dimensional reconstruction showing a posterior left elbow dislocation

the elbow has to be flexed more than  $50^\circ$  to be stable.<sup>[31]</sup> The patient should avoid hyperextension before the joint is reduced to avoid entrapping the brachial artery or the median nerve.<sup>[32]</sup> Anterior, divergent, or complex dislocations must be rushed to the operating room because of their complexity and the likelihood of more extensive damage.

When a simple dislocation is repositioned, the joint is traditionally immobilized in a static plaster for a short period of time. Shorter periods of immobilization are associated with better outcomes in terms of the range of motion.<sup>[8,33-37]</sup>

Even though in some of these studies, the difference in outcomes did not reach statistical significance, the trend is clear and consistent across different study groups. Early joint mobilization can reduce the formation of scar tissue, thus preventing chronic elbow stiffness and shortening the recovery time by half.<sup>[36]</sup> Shorter immobilization periods also lead to a better chance not to lose flexion and a decrease in the degree of pain.<sup>[34]</sup> In a randomized trial including 100 patients with elbow dislocations, de Haan *et al.*<sup>[8]</sup> started functional therapy 2 days after the reduction of the dislocation. When compared with another group that received plaster for 3 weeks, those patients that received functional therapy recovered faster without an increase in the complication rate.<sup>[38]</sup>

### Surgical management

The presence of a fracture in a complex elbow dislocation compromises joint stability and increases the incidence of chronic joint instability. Consequently, most cases are treated surgically to properly repair the anatomical support of the articulation and restore the complete range of motion of the elbow in the long term. Achieving a stable, yet fully mobile joint is challenging for the surgeon, as those two goals conflict; by early rehabilitation and minimizing the immobilization time, the best outcomes can be obtained.<sup>[12]</sup>

When elbow dislocation is associated with fractures of both the radial head and coronoid, this presentation is known as “the terrible triad of the elbow.” It carries a worse prognosis and deserves surgical treatment in nearly every case.<sup>[39]</sup>

Describing the proper surgical technique is beyond the scope of this review, but the overall goals of surgery are described below:<sup>[40]</sup>

- Stabilize the coronoid by repairing the anterior capsule or performing fracture fixation (which is entirely dependent on the type and nature of the fracture)
- Stabilize the radial head via fracture fixation or consider replacing the radial head with a metal prosthesis
- Repair the LCL complex, common extensor origin, and/or posterolateral capsule to re-establish lateral stability
- Repair the MCL in patients that exhibit posterior instability following injury, and
- Consider using a hinged external fixator when sufficient joint stability cannot be obtained by conventional methods.

### Rehabilitation

In simple elbow dislocations, or even in cases of surgical repair, active or passive mobilization of the joint can start from day one postoperatively. Avoiding splints and prolonged immobilization of the joint reduces the occurrence of elbow stiffness; this is also associated with an increased final range of motion.<sup>[40]</sup>

Inflammation control following injury is the first step toward rehabilitation. Edema and pain can limit the patient’s ability and willingness to mobilize the joint, which, in turn, can cause contraction and stiffness. The usual approach of rest, ice,

compression, and elevation is appropriate in controlling edema. Within the limits of pain, joint mobilization and manual therapy are started early. Proprioception could be stimulated effectively by initiating oscillatory motions of the elbow, which reduces muscular spasms. As the patient progresses, the mobilization techniques also adapt, increasing the speed of movement, range of motion, number of repetitions, and added resistance. These exercises are introduced to the rehabilitation regimen as the patient moves from the inflammatory to the remodeling phase of the healing process. The optimal frequency of exercising is unknown, but the usual recommendations include frequent exercises (every 2–3 h); the exercises should be done within the limits of pain and muscle fatigue without triggering inflammation. Patients should also do not forget to exercise the adjacent muscle groups, such as the shoulder, wrist, and hand.<sup>[41]</sup>

Splinting can also be used during the rehabilitation phase to increase the range of motion. To avoid worsening of inflammation and to avoid interference with the healing process, splints are indicated 3–6 weeks after injury. Numerous static and dynamic splints were designed to facilitate restoring motion to the elbow, which had stiffened due to both the trauma and prolonged immobilization. They can be used to maintain the arm in a prolonged stretch, which can increase slowly and progressively.<sup>[41]</sup> Other types of splints can be indicated to increase the range of motion in either direction to promote flexion or extension of the elbow joint. The splints have to be used for months, and the majority of patients eventually obtain a functional range of motion.<sup>[42]</sup>

Other tools that can be used to help in rehabilitation are ultrasound and neuromuscular electrical stimulation. Low-intensity ultrasound can have an anti-inflammatory effect and increase fibroblastic activity within the soft tissues, promoting healing.<sup>[43]</sup> Electrical stimulation helps by re-educating the adjacent muscles and reducing contractures caused by pain or prolonged immobilization. The trauma itself, or even immobilizing or limiting the elbow joint's mobility, can cause abnormal programming of the receptor system's function.<sup>[44]</sup>

In summary, rehabilitation should be active and started early, but the athlete should not return to the normal sport practice before 4–6 months to allow the joint to heal and prevent the risk of secondary dislocations fully.<sup>[45]</sup>

## COMPLICATIONS

### Residual pain and loss of terminal extension

A loss of 10°–15° at the terminal extension is common.<sup>[2]</sup> Prolonged immobilization and severity of the injury are two factors associated with a poorer outcome in this regard.<sup>[8]</sup> Mild cases can be managed by physiotherapy and/or extension splints. If the limitation is more than 30°, surgical intervention could be indicated; the anterior capsule is released by open or arthroscopic surgery, and any heterotopic ossification is removed.<sup>[12]</sup>

### Chronic elbow instability

The instability of the elbow joint following a dislocation is caused by damage to the restraining ligaments, as well as by associated fractures and malalignments of the bony structures. The pattern of instability most commonly seen is a posterolateral rotary instability caused by damage to the LCL.<sup>[12]</sup> Surgical intervention with the use of a hinged external fixator can be a therapeutic option.<sup>[46]</sup>

### Heterotopic ossification

A common complication of elbow dislocations is heterotopic ossification, which is seen in up to 55% of patients.<sup>[15]</sup> However, the majority of cases are not associated with symptoms. Thus, the finding of periarticular calcification, or calcium deposits within the ligaments of the elbow joint, is a mere radiologic finding during follow-up without any clinical significance. Surgical excision is recommended only in those cases where the ossification of the MCL or LCL ligaments causes significant limitation of movement.<sup>[12]</sup>

### Median nerve entrapment

Median nerve entrapment after elbow dislocations occurs almost exclusively in children. Early signs include weakness and numbness in the median nerve distribution, which may or may not be associated with varying degrees of pain. In chronic, untreated cases, other signs may be present: atrophy of the medial forearm and thenar musculature, anhidrosis in the median nerve distribution, and ulceration at the tip of the index finger.<sup>[47]</sup>

### Compartment syndrome

This is an urgent condition that requires close monitoring and surgical intervention in more severe cases. The pressure within the aponeurotic compartment increases to a point where the blood supply to the muscles of the forearm is compromised. Due to ischemia, the contractile substance of the affected muscle coagulates, disintegrates in plaque form, and is later absorbed and replaced by scar tissue – a process originally described by Volkmann.<sup>[48]</sup>

### Vascular injury

The frequency of vascular lesions associated with elbow dislocations is, fortunately, low. However, considering the anatomic proximity of periarticular neurovascular structures, such complications do occur. The ulnar and radial epiphyses, when displaced backward, can either rupture or compress the adjacent blood vessels and nerve trunks. Ayel *et al.* presented nine cases of elbow dislocations with rupture of the brachial artery and reviewed the available literature. There were a total of 39 individual cases from 1969 to 2005.<sup>[5]</sup>

## PROGNOSIS AND FOLLOW-UP

Once simple dislocations are repositioned and treated in plaster, the prognosis is good for the majority of patients; recurrent dislocations and chronic instability are not common.<sup>[15]</sup> However, studies based on patient-reported outcomes were able to detect subtle functional deficits in the affected side;

the range of motion (flexion–extension arc) and grip strength are both reduced. Almost 8% of patients in one study group showed signs of elbow instability when examined, 56% reported stiffness, and 62% complained of some degree of residual pain.<sup>[49]</sup>

It is important not to assume that patients with simple dislocations and “simple” injuries should just deal with it, especially in the context of sports. Of the patients that had an elbow dislocation associated with sports, 20% had to either give up their primary sport completely or modify their technique in order to accommodate residual symptoms and suboptimal elbow function.<sup>[49]</sup> The primary treatment and rehabilitation protocol can have a significant impact on the outcome, which can be the deciding factor of whether a young athlete pursues a professional career or not. One factor that can also influence the outcome is proper dialog between the attending physician, physical therapist, and patient. The approach and target outcomes must be tailored based on the patient’s age, occupation, individual needs, and activity level.<sup>[41]</sup>

Complex dislocations come in a variety of presentations and different classifications and are treated by various surgical techniques. Still, all studies agree that those dislocations invariably carry a worse prognosis. The presence of one or more fractures increases the risk of complications, with chronic instability and stiffness being the most common. Greater forces that cause the fractures are also to blame for increased damage to the related soft tissue and joint cartilage, leading to the consequent poor outcome.<sup>[50]</sup>

## PREVENTION

Proper treatment and rehabilitation should ensure the stability of the elbow and minimize subsequent dislocations. It also prevents known complications that carry significant morbidity, affects the athlete’s performance, and hinders the progression of his/her career. However, most cases of elbow dislocation are primary,<sup>[10]</sup> so prevention should better focus on identifying the risk factors that cause the injury in the first place. Epidemiological data are also helpful in guiding preventive strategies on sports that show a higher risk of elbow dislocations.<sup>[7]</sup>

Falling on an outstretched hand is the most frequent cause of injury and should be avoided whenever possible.<sup>[2]</sup> Knowing the most common pattern of injury,<sup>[51]</sup> the athlete can minimize the risk of injury by learning and training on the proper way to fall. In wrestling and other combat sports, for example, students learn early on in their practice that stopping a takedown with their hands is risky, and they learn the proper way of performing this maneuver. Lastly, the engineering of better playing surfaces and protection equipment certainly plays a role in minimizing the number and severity of accidents.

## CONCLUSION

Given the high prevalence of elbow dislocations related to sports, it is important to understand the associated risks, as

proper preventive measures can reduce the incidence of these injuries. By reviewing the available literature, we hope to help medical practitioners better diagnose and treat this injury and its complications. Even though it is not a life-threatening condition, severe cases can carry significant morbidity and potentially end successful sports careers prematurely.

## Ethical considerations

All images in this review are de-identified. There are no other ethical considerations as no individuals were enrolled.

## Financial support and sponsorship

Nil.

## Conflicts of interest

There are no conflicts of interest.

## Authors’ contributions

MAM conceived and designed the study, MAM and MHK conducted research, AMJ and NAH provided research materials, and collected and organized data. AFH and MAA analyzed and interpreted data. MAM and SHS wrote the initial and final draft of the article and provided logistic support. All authors have critically reviewed and approved the final draft and are responsible for the content and similarity index of the manuscript.

## REFERENCES

- Waymack JR, An J. Posterior Elbow Dislocation, in StatPearls. Treasure Island (FL). 2020.
- Kuhn MA, Ross G. Acute elbow dislocations. *Orthop Clin North Am* 2008;39:155-61, v.
- Watts AC. Primary ligament repair for acute elbow dislocation. *JBJS Essent Surg Tech* 2019;9:e8.
- Akansel G, Dalbayrak S, Yilmaz M, Bekler H, Arslan A. MRI demonstration of intra-articular median nerve entrapment after elbow dislocation. *Skeletal Radiol* 2003;32:537-41.
- Ayel JE, Bonneville N, Lafosse JM, Pidhorz L, Al Homisy M, Mansat P, *et al.* Acute elbow dislocation with arterial rupture. Analysis of nine cases. *Orthop Traumatol Surg Res* 2009;95:343-51.
- Josefsson PO, Nilsson BE. Incidence of elbow dislocation. *Acta Orthop Scand* 1986;57:537-8.
- Stoneback JW, Owens BD, Sykes J, Athwal GS, Pointer L, Wolf JM. Incidence of elbow dislocations in the United States population. *J Bone Joint Surg Am* 2012;94:240-5.
- de Haan J, den Hartog D, Tuinebreijer WE, Iordens GI, Breederveld RS, Bronkhorst MW, *et al.* Functional treatment versus plaster for simple elbow dislocations (FuncSiE): A randomized trial. *BMC Musculoskelet Disord* 2010;11:263.
- Linscheid RL, Wheeler DK. Elbow dislocations. *JAMA* 1965;194:1171-6.
- Dizdarevic I, Low S, Currie DW, Comstock RD, Hammoud S, Atanda A Jr. Epidemiology of elbow dislocations in high school athletes. *Am J Sports Med* 2016;44:202-8.
- Englert C, Zellner J, Koller M, Nerlich M, Lenich A. Elbow dislocations: A review ranging from soft tissue injuries to complex elbow fracture dislocations. *Adv Orthop* 2013;2013: Article ID: 951397.
- Saati AZ, McKee MD. Fracture-dislocation of the elbow: Diagnosis, treatment, and prognosis. *Hand Clin* 2004;20:405-14.
- Hackl M, Beyer F, Wegmann K, Leschinger T, Burkhart KJ, Müller LP. The treatment of simple elbow dislocation in adults. *Dtsch Arztebl Int* 2015;112:311-9.
- Kaufmann RA, Wilps T, Musahl V, Debski RE. Elbow biomechanics: Soft tissue stabilizers. *J Hand Surg Am* 2020;45:140-7.
- Hildebrand KA, Patterson SD, King GJ. Acute elbow dislocations:

- Simple and complex. *Orthop Clin North Am* 1999;30:63-79.
16. Hanlon DP, Mavrophilipos V. The emergent evaluation and treatment of elbow and forearm injuries. *Emerg Med Clin North Am* 2020;38:81-102.
  17. Sheps DM, Hildebrand KA, Boorman RS. Simple dislocations of the elbow: Evaluation and treatment. *Hand Clin* 2004;20:389-404.
  18. Vijayan S, Chalappurath V, Jose S, Rao SK. Anterior elbow dislocation without fracture in an adult: A rare injury pattern. *BMJ Case Rep* 2019;12. pii: e230115.
  19. Deutch SR, Olsen BS, Jensen SL, Tyrdal S, Sneppen O. Ligamentous and capsular restraints to experimental posterior elbow joint dislocation. *Scand J Med Sci Sports* 2003;13:311-6.
  20. Deutch SR, Jensen SL, Olsen BS, Sneppen O. Elbow joint stability in relation to forced external rotation: An experimental study of the osseous constraint. *J Shoulder Elbow Surg* 2003;12:287-92.
  21. O'Driscoll SW. Classification and evaluation of recurrent instability of the elbow. *Clin Orthop Relat Res* 2000;370:34-43.
  22. Cohen MS, Hastings H 2<sup>nd</sup>. Acute elbow dislocation: Evaluation and management. *J Am Acad Orthop Surg* 1998;6:15-23.
  23. Limb D, Hodkinson SL, Brown RF. Median nerve palsy after posterolateral elbow dislocation. *J Bone Joint Surg Br* 1994;76:987-8.
  24. Kansay R, Gupta S, Soni A, Malhotra A, Garg SK. Isolated anterior dislocation of the radial head with atypical presentation in an adult: A case report. *Rev Bras Ortop (Sao Paulo)* 2019;54:746-50.
  25. Frankle MA, Koval KJ, Sanders RW, Zuckerman JD. Radial head fractures associated with elbow dislocations treated by immediate stabilization and early motion. *J Shoulder Elbow Surg* 1999;8:355-60.
  26. Popovic N, Gillet P, Rodriguez A, Lemaire R. Fracture of the radial head with associated elbow dislocation: Results of treatment using a floating radial head prosthesis. *J Orthop Trauma* 2000;14:171-7.
  27. Regan W, Morrey B. Fractures of the coronoid process of the ulna. *J Bone Joint Surg Am* 1989;71:1348-54.
  28. Ring D, Jupiter JB, Simpson NS. Monteggia fractures in adults. *J Bone Joint Surg Am* 1998;80:1733-44.
  29. Hotchkiss RN. Displaced fractures of the radial head: Internal fixation or excision? *J Am Acad Orthop Surg* 1997;5:1-10.
  30. Potter HG, Weiland AJ, Schatz JA, Paletta GA, Hotchkiss RN. Posterolateral rotatory instability of the elbow: Usefulness of MR imaging in diagnosis. *Radiology* 1997;204:185-9.
  31. Hankin FM. Posterior dislocation of the elbow. A simplified method of closed reduction. *Clin Orthop Relat Res* 1984;190:254-6.
  32. Hallett J. Entrapment of the median nerve after dislocation of the elbow. A case report. *J Bone Joint Surg Br* 1981;63-B: 408-12.
  33. Maripuri SN, Debnath UK, Rao P, Mohanty K. Simple elbow dislocation among adults: A comparative study of two different methods of treatment. *Injury* 2007;38:1254-8.
  34. Mehlhoff TL, Noble PC, Bennett JB, Tullos HS. Simple dislocation of the elbow in the adult. Results after closed treatment. *J Bone Joint Surg Am* 1988;70:244-9.
  35. Rafai M, Largab A, Cohen D, Trafteh M. Pure posterior luxation of the elbow in adults: Immobilization or early mobilization. A randomized prospective study of 50 cases. *Chir Main* 1999;18:272-8.
  36. Riel KA, Bennett P. Simple elbow dislocation. Comparison of long-term results after immobilization and functional treatment. *Unfallchirurg* 1993;96:529-33.
  37. Schippinger G, Seibert FJ, Steinböck J, Kucharczyk M. Management of simple elbow dislocations. Does the period of immobilization affect the eventual results? *Langenbecks Arch Surg* 1999;384:294-7.
  38. Iordens GI, Van Lieshout EM, Schep NW, De Haan J, Tuinebreijer WE, Eygendaal D, *et al*. Early mobilisation versus plaster immobilisation of simple elbow dislocations: Results of the FuncSiE multicentre randomised clinical trial. *Br J Sports Med* 2017;51:531-8.
  39. O'Driscoll SW, Jupiter JB, King GJ, Hotchkiss RN, Morrey BF. The unstable elbow. *Instr Course Lect* 2001;50:89-102.
  40. McKee MD, Pugh DM, Wild LM, Schemitsch EH, King GJ. Standard surgical protocol to treat elbow dislocations with radial head and coronoid fractures. Surgical technique. *J Bone Joint Surg Am* 2005;87 Suppl 1:22-32.
  41. Chinchalkar SJ, Szekeres M. Rehabilitation of elbow trauma. *Hand Clin* 2004;20:363-74.
  42. Gelinas JJ, Faber KJ, Patterson SD, King GJ. The effectiveness of turnbuckle splinting for elbow contractures. *J Bone Joint Surg Br* 2000;82:74-8.
  43. Nussbaum E. The influence of ultrasound on healing tissues. *J Hand Ther* 1998;11:140-7.
  44. Häggmark T, Eriksson E, Jansson E. Muscle fiber type changes in human skeletal muscle after injuries and immobilization. *Orthopedics* 1986;9:181-5.
  45. Shanmugam C, Maffulli N. Sports injuries in children. *Br Med Bull* 2008;86:33-57.
  46. McKee MD, Bowden SH, King GJ, Patterson SD, Jupiter JB, Bamberger HB, *et al*. Management of recurrent, complex instability of the elbow with a hinged external fixator. *J Bone Joint Surg Br* 1998;80:1031-6.
  47. Simon D, Masquijo JJ, Duncan MJ, Kontio K. Intra-articular median nerve incarceration after spontaneous reduction of a pediatric elbow dislocation: Case report and review of the literature. *J Pediatr Orthop* 2010;30:125-9.
  48. Reurings JC, Verhofstad MH. The Volkmann ischemic contracture of the forearm is preventable. *Eur J Trauma Emerg Surg* 2007;33:539-44.
  49. Anakwe RE, Middleton SD, Jenkins PJ, McQueen MM, Court-Brown CM. Patient-reported outcomes after simple dislocation of the elbow. *J Bone Joint Surg Am* 2011;93:1220-6.
  50. Jennings JD, Hahn A, Rehman S, Haydel C. Management of adult elbow fracture dislocations. *Orthop Clin North Am* 2016;47:97-113.
  51. de Haan J, Schep NW, Zengerink I, van Buijtenen J, Tuinebreijer WE, den Hartog D. Dislocation of the elbow: A retrospective multicentre study of 86 patients. *Open Orthop J* 2010;4:76-9.