



Original Article

Use of cemented standard stem arthroplasty for unstable intertrochanteric fractures in elderly patients: A pilot study

Mohamed I Elashmawy, MD.¹, Mohamed A R Mostafa, MD.²

¹Department of Orthopedics, Dar Elshefa Hospital, Ministry of Health, ²Department of Orthopedic Surgery, Ain Shams University, Cairo, Egypt.

***Corresponding author:**

Mohamed I Elashmawy, MD.
Department of Orthopedics,
Dar Elshefa Hospital, Ministry
of Health, Cairo, Egypt.

dr.m.elashmawy@gmail.com

Received: 25 November 2024
Accepted: 09 February 2025
Epub ahead of print: 25 March 2025
Published: 02 April 2025

DOI
10.25259/JMSR_526_2024

Quick Response Code:



ABSTRACT

Objectives: The objective of this study was to assess the use of cemented standard stem arthroplasty for treating intertrochanteric fractures in old-aged patients.

Methods: This was a single-arm clinical trial on 20 patients with unstable intertrochanteric fractures. The study's inclusion criteria encompassed both sexes, individuals over 60 years old, and those with unstable intertrochanteric femoral fractures. The study excluded individuals with pathological fractures, those with concomitant shaft fractures, and those who denied informed consent. The duration of the study was 12 months. Six months after the operation, the first follow-up radiograph was performed, then after another 6 months, a final follow-up radiograph was performed at 12 months follow-up.

Results: There was a high statistically significant difference in Harris's hip score at different times (post-operative, at 6 months, and 12 months).

Conclusion: Cemented standard stem arthroplasty is a good option for unstable-type intertrochanteric fractures in older patients.

Keywords: Arthroplasty, Cemented, Elderly, Geriatric fractures, Intertrochanteric, Standard stem, Unstable

INTRODUCTION

With the coming of an aging society, the incidence of intertrochanteric fracture in elderly patients (patients above the age of 80 years) is increasing. Surgical treatment enables patients to start functional training earlier, which reduces the complications caused by long-term bed rest and mortality significantly.^[1]

The risk of hip fracture in old patients is elevated even with small traumatic events due to osteoporosis. Furthermore, early intervention could be challenging due to existing comorbidities.^[2]

Despite surgical intervention, achieving good fixation remains challenging due to osteoporosis. Furthermore, diminished mobility post-surgery may elevate the incidence of complications such

How to cite this article: Elashmawy MI, Mostafa MA. Use of cemented standard stem arthroplasty for unstable intertrochanteric fractures in elderly patients: A pilot study. J Musculoskelet Surg Res. 2025;9:244-50. doi: 10.25259/JMSR_526_2024

as pressure sores or pneumonia and maybe death. These complications usually extend the hospital stay and increase the treatment expenses while also contributing to a greater total socioeconomic burden.^[3] Consequently, many authors have tested different approaches to improve outcomes for hip fractures and enhance post-operative mobilization without impacting mortality.^[4,5]

Hip fractures potentially result in mortality. Mortality rates among the elderly after hip fractures reach up to 14–36% within 1 year of the fracture. Elderly people encounter a 5-8-fold increased mortality risk within the first 3 months following a fracture. The increased mortality risk lasts for up to 10 years. Due to the anticipated rise in life expectancy in Western nations over the coming decades, hip fractures and their consequences will greatly affect health systems and society.^[6]

Internal fixation is generally utilized as the main surgical modality for intertrochanteric fractures.^[7] Notably, many authors demonstrated better outcomes, while others documented significant failure rates in unstable types. These failure rates were mentioned in literature studies, which showed cutout percentages of 8% for dynamic hip screws (DHS), 20% for malunion and osteosynthesis fatigue, and an incidence of coxa vara, delayed healing, or nonunion ranging from 36% to 54%.^[7] Consequently, Fichman *et al.* showed that arthroplasty could decrease non-weight-bearing duration, decrease the incidence of implant-associated complications, and support hip functionality compared to internal fixation using DHS, Gamma nails, and proximal femoral nails.^[8]

Although arthroplasty is a technically challenging procedure, it is associated with reduced complication rates if done perfectly. The literature provides sufficient evidence to recommend arthroplasty as a major treatment modality for these fractures. Primary prosthetic replacement is the preferred procedure since it facilitates early weight-bearing and eliminates concerns with varus collapse of the fracture fragment. In patients undergoing arthroplasty, rehabilitation is faster, and problems such as pressure ulcers, pulmonary infections, and atelectasis are significantly reduced. It facilitates a prompt return to pre-fracture activity levels and effectively mitigates the exacerbation of concomitant disorders. The capacity to weight-bear during the early post-operative phase is crucial for the effectiveness of arthroplasty.^[9]

Our study aimed to measure functional outcomes after cemented hip arthroplasty with a cemented standard femoral stem to manage intertrochanteric femur fractures.

MATERIALS AND METHODS

We conducted a pilot study prospectively on 20 patients with intertrochanteric fractures [unstable type (Evan's

classification)] with lost follow-up of two patients [Figure 1]. We took a complete medical history, performed a detailed physical examination, and performed radiological assessments, including anteroposterior and lateral views of the pelvis and both hips, to evaluate all patients for eligibility. The study's inclusion criteria encompassed both sexes, individuals over 60 years old, and those with unstable intertrochanteric femoral fractures. The study excluded individuals with pathological fractures, those with concomitant shaft fractures, and those who denied informed consent. All cases were done with a lateral approach using a primary cemented stem. In some cases, the greater trochanter was reconstructed with K-wires. However, cases with comminuted fracture type were managed with soft-tissue repair, intraosseous sutures, and without fixing the posteromedial fragment.

Data management and statistical analysis

Data gathered historically, fundamental clinical assessments, laboratory analyses, and outcome metrics were transcribed, inputted, and analyzed utilizing Microsoft Excel software. The data were subsequently imported into the Statistical Package for the Social Sciences version 20.0 for analysis. Qualitative data are represented as numbers and percentages, while quantitative data are shown as mean \pm standard deviation (SD). Pearson's correlation or Spearman's correlation for correlation analysis was employed to assess significance. $P < 0.05$ was considered statistically significant, and $P < 0.01$ was highly significant.

Descriptive statistics

Mean, standard deviation (\pm SD), and range were utilized for parametric numerical data, while median and interquartile range were employed for non-parametric numerical data.

Analytical statistics

We used the Kruskal–Wallis test to assess the statistical significance of the difference of a non-parametric variable between more than two study groups.^[10]

RESULTS

The primary results of the study demonstrated that the mean age of the study population was 74.25 years (± 6.95 SD), ranging from 60 to 89 years. Among the cases, 13 females (65%) and 7 males (35%) were diagnosed with unstable intertrochanteric fractures.

Of the cases examined, 10 (50%) had diabetes, 6 (30%) had hypertension, 2 (10%) had deep vein thrombosis (DVT), 5 (25%) had ischemic heart disease (ISC), 1 (5%) had severe osteoarthritis of the knee, 1 (5%) had coagulopathy, 1 (5%)

had renal impairment, 1 (5%) had chronic renal failure, and 1 (5%) had a history of stroke.

Of the cases operated on, ten patients were operated on for total hip arthroplasty with cemented cup (five had pre-operative hip arthritis, five with pre-operative high activity level) and ten patients were operated hemiarthroplasty (low demand patients, with no hip arthritis [Table 1].

Trochanteric fixation was done with intraosseous soft-tissue reconstruction in 15 patients, and fixation with K-wires was done in five patients [Table 2]. The mean operative

time for the studied patients was 2.05 h (± 0.48 SD), with a range of 1.5–3 h, while the average blood loss was 830 mL (± 230.2 SD), with a range of 500–1500 mL.

Only one patient experienced dislocation 2 weeks post-operative after new trauma, necessitating closed reduction [Figure 2]. Two patients lost follow-up, one patient died after 2 months, and the other died after 40 days.

Over follow-up intervals. A highly statistically significant difference was noted in the Harris hip score (HHS) (post-operative, at 6 months and 12 months) [Tables 3-5].

Table 1: Prosthesis choice.

Prosthesis choice	No of patients	Reason
Total hip arthroplasty (with cemented cup)	10	High activity level pre-operative Pre-operative hip arthritis
Bipolar hemiarthroplasty	10	Low demand activity No arthritis

Table 2: Trochanteric fixation.

Technique	No. of patient
Soft-tissue reconstruction intra osseous sutures	15
Reconstruction with K-wires	5

DISCUSSION

Intertrochanteric fractures are among the most prevalent fracture forms encountered by orthopedic specialists. These fractures are increasingly prevalent as the life span increases. By 2040, the rate of hip fractures is anticipated to increase two-fold due to a reduction in muscle mass around the hip and the increasing frequency of osteoporosis, correlated with the aging population.^[11]

Unstable intertrochanteric fractures in old-aged people with osteoporosis exhibit significant displacement and comminution. Achieving and maintaining anatomic reduction of fractures is challenging, frequently resulting in malunion, reduction failure, and the necessity for re-operation. Furthermore, the absence of early ambulation postoperatively contributes to

Table 3: Comparison between the three periods according to mobilization.

Mobilization	First 2 months		After 6 months		After 1 year		Fr	P-value
	No.	%	No.	%	No.	%		
With no aid	0	0.0	0	0.0	10	50.0	33.50*	<0.001*
One crutch	0	0.0	18	100.0	8	40.0		
Two crutches	18	100.0	0	0.0	0	0.0		

Pairwise $P_1 < 0.001^*$, $P_2 < 0.001^*$, $P_3 = 0.096$

Fr: Friedman test, Sig. bet. periods was done using the *post hoc* test (Dunn's). P_1 : P-value for comparing between first 2 months and after 6 months.

P_2 : P-value for comparing between first 2 months and after 1 year. P_3 : P-value for comparing between after 6 months and after 1 year. *Statistically significant at $P \leq 0.05$

Table 4: Relation between HHS and mobilization.

Mobilization	HHS								χ^2	P-value
	Excellent (>90)		Good (81–90)		Fair (71–80)		Poor (≤ 70)			
	No.	%	No.	%	No.	%	No.	%		
After 6 months	(n=0)		(n=0)		(n=14)		(n=4)		–	–
With no aid	–	–	–	–	0	0.0	0	0.0		
One crutch	–	–	–	–	14	100.0	4	100.0		
After 1y	(n=9)		(n=8)		(n=1)		(n=0)		1.385	^{MC} $P=0.801$
With no aid	5	55.6	5	62.5	0	0.0	–	–		
One crutch	4	44.4	3	37.5	1	100.0	–	–		

χ^2 : Chi-square test, MC: Monte Carlo, HHS: Harris Hip score

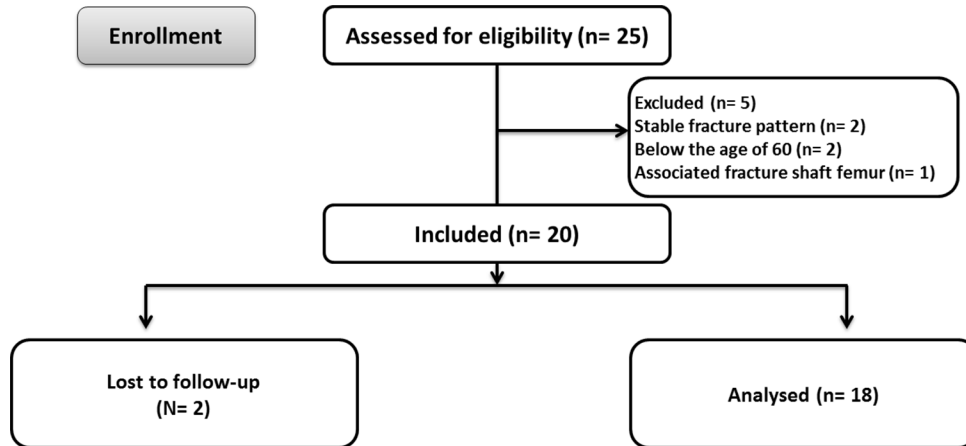


Figure 1: Flowchart of the pilot study on patients with intertrochanteric fractures.

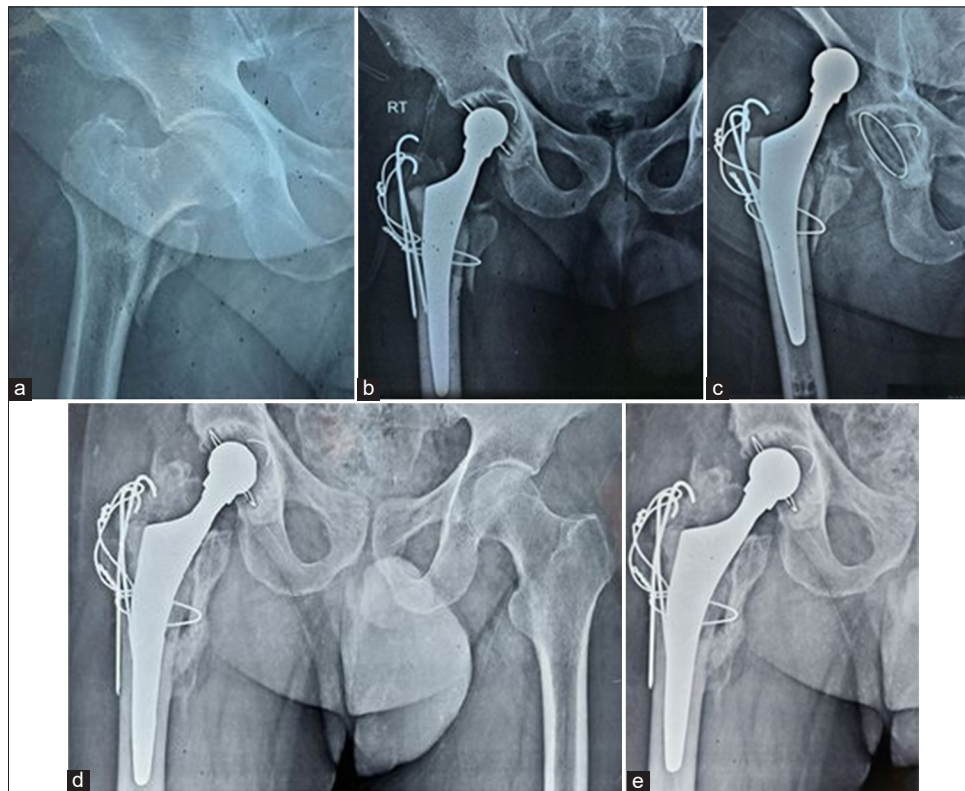


Figure 2: (a) A pre-operative radiograph of a 75-year-old male with recent right unstable intertrochanteric femur fracture. (b) Post-operative radiograph showing cemented total hip arthroplasty with trochanteric fixation with K-wires. (c) Two weeks post-operative the patient fell to the ground and presented with hip dislocation. (d) 6-month follow-up after closed reduction showing well-fixed component, no signs of loosening, fully united trochanter. (e) One-year follow-up showing well-fixed component, no signs of loosening, and a fully united trochanter.

elevated incidence of complications and mortality, particularly in conjunction with other comorbidities.^[12]

Primarily, the main objective is to restore pre-fracture mobility and functionality as soon as possible to mitigate mortality and morbidity. Early mobilization

and rehabilitation in the post-operative period should be considered when evaluating management choices.^[13]

Intertrochanteric fractures constitute around 45–50% of all hip fractures in old-aged people, with 50–60% categorized as unstable. The cut-out rate for DHS can reach 8% in

Table 5: Comparison between the three periods according to HHS.

HSS	6 weeks		6 months		1 year		Test of Sig.	P-value
	No.	%	No.	%	No.	%		
Categories								
Excellent (>90)	0	0.0	0	0.0	9	50.0	Fr=33.701*	<0.001*
Good (81–90)	0	0.0	0	0.0	8	44.4		
Fair (71–80)	0	0.0	14	77.8	1	5.6		
Poor (≤70)	18	100.0	4	22.2	0	0.0		
Sig. bet. Periods	$P_1=0.016^*$, $P_2<0.001^*$, $P_3=0.002^*$							
Score								
Min.–Max.	55.0–68.0		69.0–80.0		80.0–96.0		F=336.55*	<0.001*
Mean±SD.	61.61±3.88		74.61±3.53		90.28±3.64			
Median (IQR)	61.5 (58.0–65.0)		75.0 (72.0–77.0)		91.0 (88.0–92.0)			
Pairwise	$P_1<0.001^*$, $P_2<0.001^*$, $P_3<0.001^*$							
HHS: Harris Hip score, IQR: Interquartile range, SD: Standard deviation. Fr: Friedman test, Sig. bet. Periods was done using the <i>post hoc</i> test (Dunn's). F: F test (ANOVA) with repeated measures, Sig. bet. Periods was done using the <i>post hoc</i> test (adjusted Bonferroni). P_1 : P-value for comparing between 6 weeks and 6 months. P_2 : P-value for comparing between 6 weeks and 1 year. P_3 : P-value for comparing between 6 months and 1 year. *Statistically significant at $P\leq 0.05$								

stable fracture type, while the failure rate for unstable intertrochanteric fractures may reach up to 50%.^[7]

Treating elderly patients with intertrochanteric fractures may provide challenges in attaining anatomical reduction due to the elevated morbidity and mortality rates linked to these injuries.^[14] Different types of intertrochanteric fractures are mainly treated with DHS, with more side effects in unstable fractures. The main culprit of these failures was previously proposed to be the extramedullary implants. However, a recent study found little significant difference between intra- and extramedullary types of implants.^[15]

The main objective of management is to achieve efficient and safe mobilization while reducing the risk of medical complications. The patient's capacity to regain ambulation is contingent on the integrity of the bone and the nature of the implant utilized. Patients may achieve a quicker recovery to their pre-injury activity level with primary bipolar arthroplasty treatment, thereby circumventing post-operative complications associated with immobilization or implant failure.^[16]

A surgeon can efficiently employ the standardized surgical technique to insert Gamma nails, yielding few incisions postoperatively. This treatment is not suggested if the medullary canal is narrow or blocked. Problems of the proximal femoral nail encompass fractures of the distal shaft, aggravated intertrochanteric fractures, failure of the principal nail, and varus collapse of fractures. The length and position of the lag screws presents a critical factor.^[17]

The failure rate of DHS fixation in osteoporotic fractures ranges from 3% to 26%. A solitary DHS fixation is insufficient for securely anchoring the lesser trochanter in an unstable

intertrochanteric fracture, as the posteromedial buttress acts as the main support for load bearing.^[17]

In our study, cemented standard stem arthroplasty was performed through a lateral approach for 20 patients who had unstable intertrochanteric femur fractures. We proposed that cemented arthroplasty achieves good clinical outcomes, including rapid post-operative mobilization, which significantly impacts the patient's general condition and time to recover post-operative.

El-Soufy *et al.*^[17] attempted to assess the safety and effectiveness of a novel surgical intervention for intertrochanteric fractures in the elderly undergoing cemented arthroplasty. Their study involved 18 patients who underwent primary cemented arthroplasty to stabilize unstable intertrochanteric femoral fractures for 6 months with focused clinical and radiological monitoring. The clinical evaluation was conducted with the HHS. Their analysis indicated that the mean age of the examined cohort was 74.6 ± 39 . Two-thirds of the cases were females. Cemented arthroplasty constituted 61.1%, while cemented arthroplasty with calcar replacement accounted for 38.9% of the treatment approach. Most of the investigated group (41.2%) achieved an outstanding HHS, followed by 35.3% with a good score, 17.6% with a fair score, and 5.9% with a poor score, resulting in a mean HHS of 83.23. They considered that primary hemiarthroplasty in unstable fractures in old-aged patients is considered a better option than ORIF.^[17]

Saoudy and Salama^[18] studied 30 patients with proximal extracapsular femoral fractures who had hemiarthroplasty. Twenty-two males and eight females, with an average age of 60, underwent primary cemented hemiarthroplasty through

the Hardinge lateral approach in a lateral decubitus position. The HHS was employed to assess the patients clinically. The final outcomes of the HHS varied from 93 to 54, with a mean of 79.5. Post-operative radiographs indicated optimal positioning in all cases.

They reported that four individuals experienced complications: two patients had infections, one had loosening, and the other had acetabular wear. A revision was delivered in one patient due to loosening. The final assessment of primary cemented arthroplasty is that it is an advantageous option for old-aged patients with unstable intertrochanteric fractures, as it is time-efficient and cost-effective, with few severe consequences.^[18]

Hassankhani *et al.*^[19] conducted a prospective study and follow-up of 80 old patients with unstable intertrochanteric fractures. The patients were divided into two groups: A with DHS and B with arthroplasty. The total incidence of device-related problems was considerably greater in the DHS Group. The arthroplasty group exhibited higher functional scores; nevertheless, this difference lacked statistical significance. Arthroplasty serves as an alternate intervention for older patients with unstable intertrochanteric fractures, yielding favorable clinical outcomes alongside low complication and mortality rates.^[19]

A retrospective comparison was conducted by Esen *et al.*^[20] on 127 patients treated for proximal femur fractures between 2008 and January 2011, focusing on intraoperative mortality, total mortality, and the monthly distribution of death rates.

Patients were categorized into two groups: the fixation group and the cemented bipolar with calcar replacement group.

The two groups were evaluated based on operation duration, need for blood transfusion, length of hospital stay, functional outcome, life quality, complication and revision rates, and operational expenses. Both fixation and cemented arthroplasty with calcar replacement were effective methods for treating intertrochanteric femoral fractures. Internal fixation is more suitable for geriatric fractures due to reduced operative time and re-operation likelihood.

Gashi *et al.*^[21] studied 98 patients with hip intertrochanteric fractures who were treated with either DHS or a hemiarthroplasty procedure at three hospitals over 2 years.^[21] The researchers compared the two groups based on factors such as age, sex, medical conditions, type of injury, and fracture severity. The study found that patients who underwent hemiarthroplasty could start walking with partial weight-bearing much sooner than those treated with DHS. While mortality rates were similar between the two groups, complications such as health issues and mechanical problems were more frequent in the fixation group. In addition, patients in the arthroplasty group reported better overall hip function as measured by the HHS.

They reported that cemented hemiarthroplasty is a reliable and safe method for managing unstable hip fractures. While it offers certain advantages over DHS procedures, they recommended further research to confirm its superiority.^[21]

While factors such as younger age, good health, and patient cooperation can influence the outcome of hip fracture treatment, surgical planning and technique are equally important. In particular, arthroplasty might be a better choice for patients with severe osteoporosis, as it may lead to better functional outcomes compared to fixation methods.

CONCLUSION

Cemented arthroplasty is an efficient treatment modality for unstable intertrochanteric femur fractures in the elderly when compared to internal fixation. Cemented fixation is better in elderly patients with radiological findings of osteoporosis. The post-operative outcome of cemented arthroplasty is influenced by age and sex, as well as their comorbidities.

Recommendations: We recommend an extended follow-up study of cemented arthroplasty outcomes in intertrochanteric fractures in elderly patients. The study should evaluate the implant's resilience and assess the patient's performance. We also recommend conducting it on a larger scale.

Authors' contributions: MIE: Conceived and designed the study, conducted research, provided research materials, and collected and organized data. MAE: Analyzed and interpreted data. MIE and MAE: Wrote the initial and final draft of the article and provided logistic support. Both authors have critically reviewed and approved the final draft and are responsible for the manuscript's content and similarity index.

Ethical approval: The research/study approved by the Institutional Review Board at Research Ethics Committee of Ain Shams University, number MD 41/2020, dated February 2, 2020.

Declaration of patient consent: The authors certify that they have obtained all appropriate patient consent forms. In the form, the patients have given their consent for their images and other clinical information to be reported in the journal. The patients understand that their names and initials will not be published, and due efforts will be made to conceal their identity, but anonymity cannot be guaranteed.

Use of artificial intelligence (AI)-assisted technology for manuscript preparation: The authors confirm that there was no use of artificial intelligence (AI)-assisted technology for assisting in the writing or editing of the manuscript and no images were manipulated using AI.

Conflicts of interest: There are no conflicting relationships or activities.

Financial support and sponsorship: This study did not receive any specific grant from funding agencies in the public, commercial or not-for-profit sectors.

REFERENCES

- Cui Q, Liu YS, Li DF, Zhang P, Guo J, Liu C, *et al.* Cemented hip hemiarthroplasty clinical observations on unstable intertrochanteric fracture in elderly. *Eur J Trauma Emerg Surg* 2016;42:651-6.
- Kim SY, Kim YG, Hwang JK. Cementless calcar-replacement hemiarthroplasty compared with intramedullary fixation of unstable intertrochanteric fractures: A prospective, randomized study. *JBJS* 2005;87:2186-92.
- Ju DG, Rajae SS, Mirocha J, Lin CA, Moon CN. Nationwide analysis of femoral neck fractures in elderly patients: A receding tide. *JBJS* 2017;99:1932-40.
- Mansukhani SA, Tuteja SV, Kasodekar VB, Mukhi SR. A comparative study of the dynamic hip screw, the cemented bipolar hemiarthroplasty and the proximal femoral nail for the treatment of unstable intertrochanteric fractures. *J Clin Diagn Res* 2017;11:RC14
- Luo X, He S, Zeng D, Lin L, Li Q. Proximal femoral nail antirotation versus hemiarthroplasty in the treatment of senile intertrochanteric fractures: Case report. *Int J Surg Case Rep* 2017;38:37-42.
- Klestil T, Röder C, Stotter C, Winkler B, Nehrer S, Lutz M, *et al.* Impact of timing of surgery in elderly hip fracture patients: A systematic review and meta-analysis. *Sci Rep* 2018;8:13933.
- Yoo JI, Cha YH, Kim KJ, Kim HY, Choy WS, Hwang SC. Comparison between cementless and cemented bipolar hemiarthroplasty for treatment of unstable intertrochanteric fractures: systematic review and meta-analysis. *Hip Pelvis* 2018;30:241-53.
- Fichman SG, Mäkinen TJ, Safir O, Vincent A, Lozano B, Kashigar A, *et al.* Arthroplasty for unstable pertrochanteric hip fractures may offer a lower re-operation rate as compared to cephalomedullary nailing. *Int Orthop* 2016;40:15-20.
- Thakur A, Lal M. Cemented hemiarthroplasty in elderly osteoporotic unstable trochanteric fractures using fracture window. *Malays Orthop J* 2016;10:5.
- Vishwanathan K, Akbari K, Patel AJ. Is the modified Harris hip score valid and responsive instrument for outcome assessment in the Indian population with pertrochanteric fractures? *J Orthop* 2018;15:40-6.
- Bzovsky S, Bhandari M. Cochrane in CORR®: Arthroplasties for hip fractures in adults. *Clin Orthop Relat Res* 2022;480:1046-52.
- Kim JT, Kim HH, Kim JH, Kwak YH, Chang EC, Ha YC. Mid-term survivals after cementless bipolar hemiarthroplasty for unstable intertrochanteric fractures in elderly patients. *J Arthroplasty* 2018;33:777-82.
- Stappaerts KH, Deldycke J, Broos PL, Staes FF, Rommens PM, Claes P. Treatment of unstable pertrochanteric fractures in elderly patients with a compression hip screw or with the Vandeputte (VDP) endoprosthesis: A prospective randomized study. *J Orthop Trauma* 1995;9:292-7.
- Cici H, Bektas YE, Demirkiran ND, Ozmanevra R. Primary arthroplasty or internal fixation in intertrochanteric femur fractures: A survey of surgical attitudes of orthopedic surgeons in Turkey. *Geriatrics* 2022;7:18.
- Sooraj SAG, Khader FA, Ramesh P, Girikrishnan A. A narrative review on functional outcome of intertrochanteric fractures treated with proximal femoral nailing. *Int J Orthop* 2022;8:185-8.
- Mahajan NP, Bagimani PK, Pande KP, Dadhaniya RR. Bipolar hemiarthroplasty as coxofemoral bypass technique in treating unstable pertrochanteric comminuted fracture of elderly patients. *J Evol Med Dent Sci* 2021;10:3683-9.
- El-Soufy MA, Nafea WM, Almahrouq MA, Ibrahim MH. Evaluation of outcomes of bipolar hemiarthroplasty in unstable intertrochanteric fractures in among elder patients. *Egypt J Hosp Med* 2022;87:1561-68.
- Saoudy EE, Salama AM. Bipolar hemiarthroplasty for the treatment of unstable trochanteric fracture femur in the elderly. *Egypt Orthop J* 2016;51:313-8.
- Hassankhani EG, Omid-Kashani F, Hajitaghi H, Hassankhani GG. How to treat the complex unstable intertrochanteric fractures in elderly patients? DHS or arthroplasty. *Arch Bone Joint Surg* 2014;2:174.
- Esen E, Dur H, Ataoğlu MB, Ayanoğlu T, Turanlı S. Evaluation of proximal femoral nail-antirotation and cemented, bipolar hemiarthroplasty with calcar replacement in treatment of intertrochanteric femoral fractures in terms of mortality and morbidity ratios. *Joint Dis Relat Surg* 2017;28:35-40.
- Gashi YN, Elhadi AS, Elbushra IM. Outcome of primary cemented bipolar hemiarthroplasty compared with dynamic hip screw in elderly patients with unstable intertrochanteric fracture. *Malays Orthop J* 2018;12:36.