

Radiology Quiz

A teenager with neck pain – A twist in the tale

Ganesh Singh Dharmshaktu, M.S. (Ortho)

Department of Orthopedics, Government Medical College, Haldwani, Uttarakhand, India.

*Corresponding author:

Ganesh Singh Dharmshaktu,
Department of Orthopedics,
C/O Dr. Y. P. S. Pangtey,
Ganga Vihar, (Near Panchakki
Chauraha), Malli Bamori,
Haldwani, Uttarakhand,
India.

drganeshortho@gmail.com

Received: 31 July 2021

Accepted: 15 August 2021

EPub Ahead of Print: 30 Aug 2021

Published:

DOI

10.25259/JMSR_95_2021

Quick Response Code:



HISTORY

An adolescent boy presented with acute neck pain and stiffness a few days following the treatment for acute bacterial meningitis was over. He had a spasm of neck muscles and tenderness without any trauma or triggering event.

- What is the finding in imaging?
- What is the diagnosis?

FINDING

The radiographs show atraumatic eccentric position of the dens of the first cervical vertebra within the axis, the second cervical vertebra [Figure 1]. Magnetic resonance imaging confirms it and also reveals inflammatory edema surrounding the dens and adjoining cervical musculature [Figure 2].

DIAGNOSIS

Non-traumatic atlantoaxial rotatory subluxation or Grisel's syndrome.

PEARLS AND DISCUSSION

Grisel's syndrome presents as sudden onset painful torticollis, neck rigidity, and decreased neck mobility of neck due to uncertain etiopathology.^[1] The clinical complaints usually follow an infective or inflammatory disorders of the head and neck or nasopharyngeal region.^[2] It is also reported after surgeries of the ear, nose, and throat region. The condition is mostly noticed in children, but adults are also reported to be affected. Conservative therapy with pain medication, immobilization, cervical traction, or braces is initially tried, whereas surgery is reserved for severe unresponsive cases. No guidelines, however, for its management are currently available. Early diagnosis and treatment, however, is critical for a good outcome.

Various reasons favor the occurrence of Grisel's syndrome in children. Some of them described are as follows:^[3]

- Immature bone and weaker cervical muscles
- Greater ligamentous laxity of the cervical spine
- Hypermobile C1 over C2 and greater atlas-dens interval
- Horizontal orientation of facet joints
- Larger synovial folds in occipito-atlanto-axial joints

How to cite this article: Dharmshaktu GS. A teenager with neck pain – A twist in the tale. J Musculoskelet Surg Res, doi: 10.25259/JMSR_95_2021

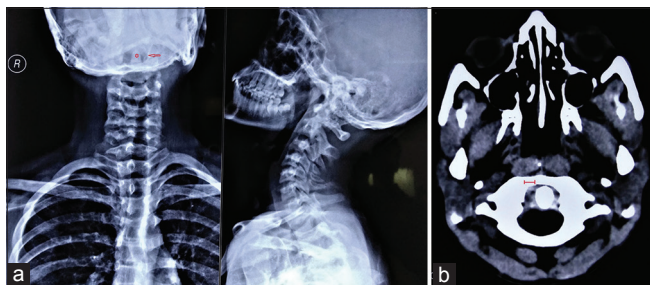


Figure 1: The cervical spine radiographs (a) in orthogonal planes show the eccentric position of dens (denoted by asterisk) with respect to the axis bone with decreased space on the left side (arrow). The lateral radiograph does not provide any significant additional information. The axial CT image (b) showing confirmation of eccentric dens position and increased space noted on the right side (denoted by red line).

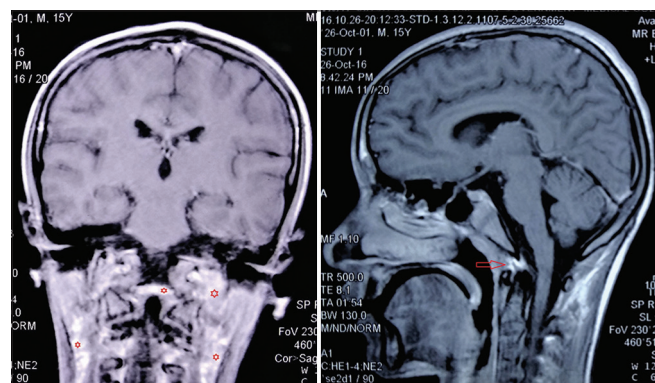


Figure 2: The coronal MRI images (first image) showing edema above dens and surrounding cervical spine region (multiple asterisks). The sagittal section image shows edema around the tip of dens (arrow).

- Higher rate of upper respiratory tract infections
- Adenotonsillar hypertrophy.

One of the many hypotheses is inflammation-induced laxity of cervical spine ligaments. A preexisting ligamentous laxity (“the first hit”) favors the causation, which is commonly found in children. Inflammatory mediators through pharyngovertebral plexus reach cervical muscles and induce spasm (“second hit”), leading to varying degrees of subluxation.^[4] Cervical spine instability can also result from manual manipulation practices like neck cracking. These

practices, though beneficial in trained hands, may rarely result in grave complications in conditions prone to serious instability like Grisel’s syndrome. Social education and expert consultation at grassroot level may prevent inappropriate treatment of many musculoskeletal disorders.

AUTHOR’S CONTRIBUTION

The author has collected the data, critically reviewed, and approved the final draft and is responsible for the manuscript’s content and similarity index.

Declaration of patient consent

The author certifies that he has obtained all appropriate patient consent forms. In the form, the patient’s parents have given their consent for his images and other clinical information to be reported in the journal. The parents understand that his name and initials will not be published and due efforts will be made to conceal his identity, but anonymity cannot be guaranteed.

Financial support and sponsorship

This study did not receive any specific grant from funding agencies in the public, commercial, or not-for-profit sectors.

Conflicts of interest

There are no conflicts of interest.

REFERENCES

1. Iccarino C, Francesca O, Piero S, Monica R, Armando R, de Bonis P, *et al.* Grisel’s syndrome: Non-traumatic atlantoaxial rotator subluxation-report of five cases and review of the literature. *Acta Neurochir Suppl* 2019;125:279-88.
2. Dagtekin A, Kara E, Vayisoglu Y, Koseoglu A, Avci E, Talas D, *et al.* The importance of early diagnosis and appropriate treatment in Grisel’s syndrome: Report of two cases. *Turk Neurosurg* 2011;21:680-4.
3. Pini N, Ceccoli M, Bergonzini P, Iughetti L. Grisel’s syndrome in children: Two case reports and systematic review of the literature. *Case Rep Pediatr* 2020;2020:8819758.
4. Battiata AP, Pazos G. Grisel’s syndrome: The two-hit hypotheses-a case report and literature review. *Ear Nose Throat J* 2004;83:553-5.