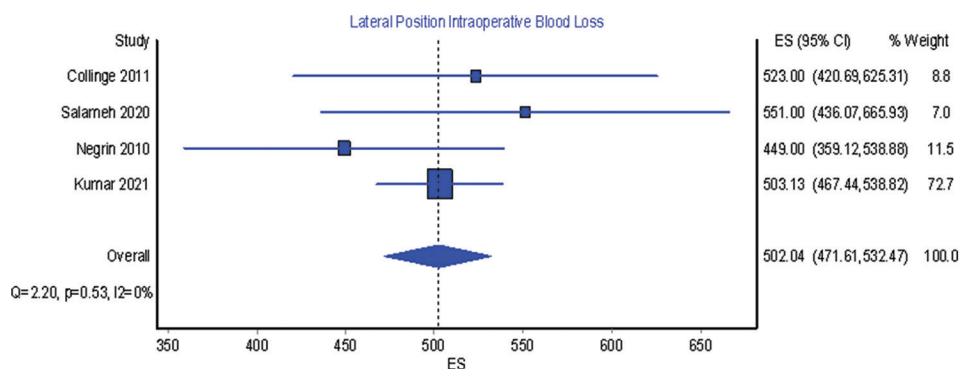
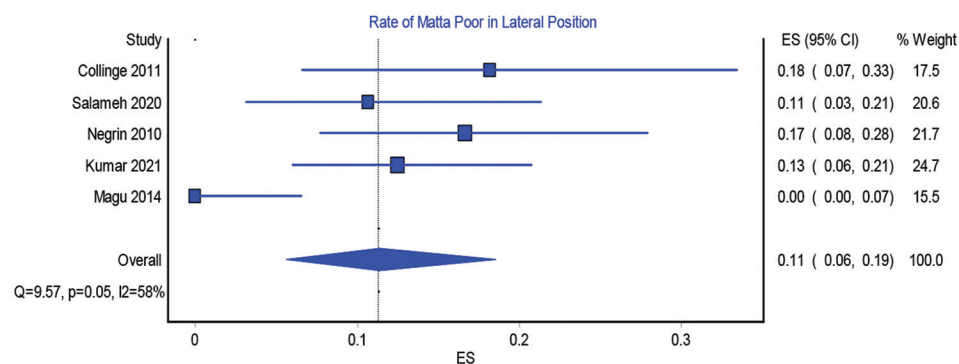
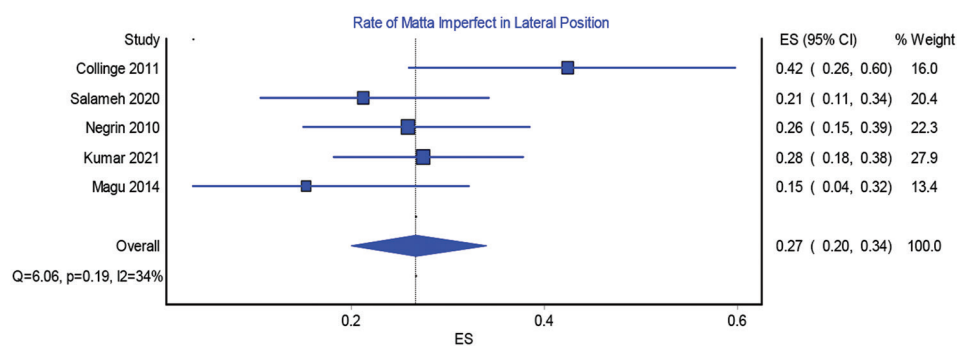
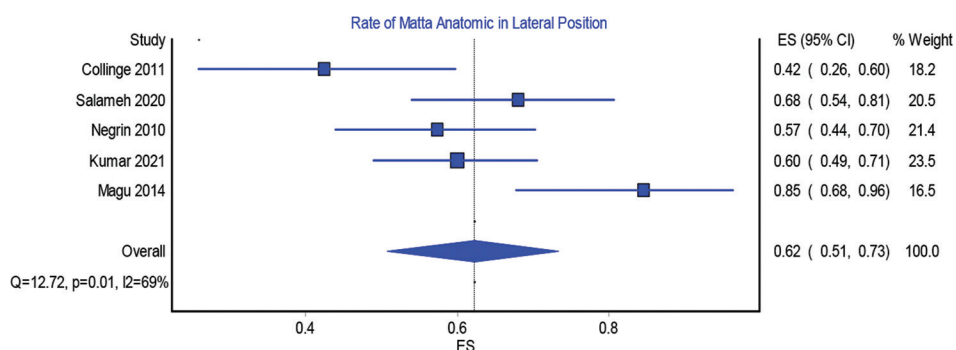


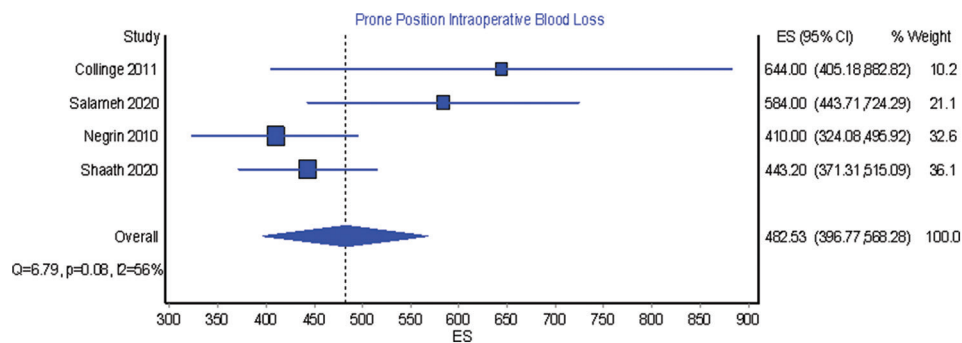
SUPPLEMENTARY MATERIAL



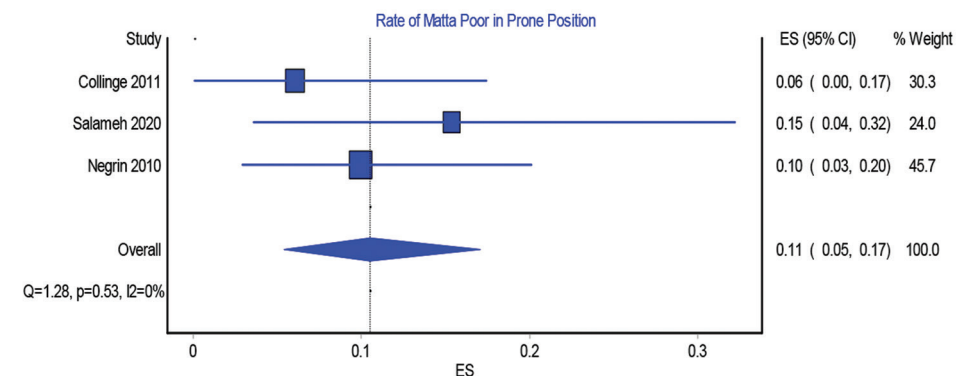
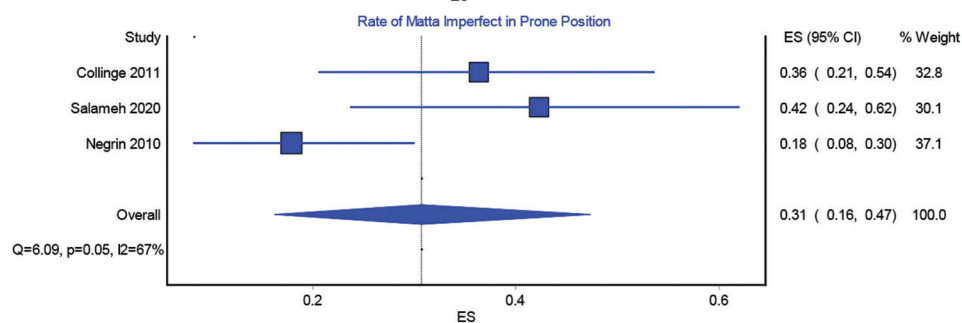
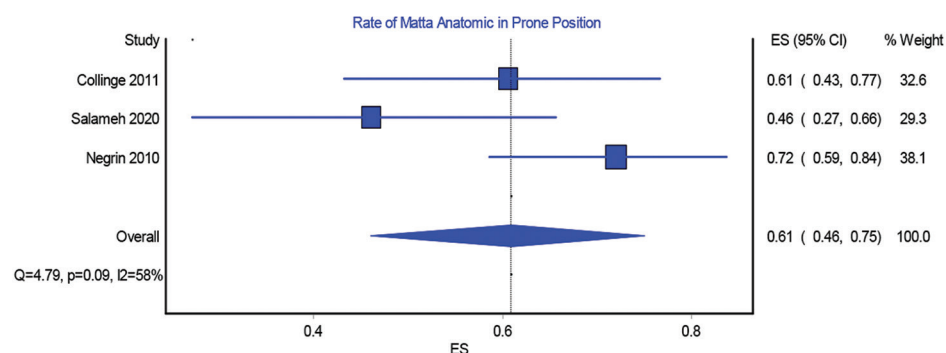
Supplementary Figure 1: Lateral position intraoperative blood loss.



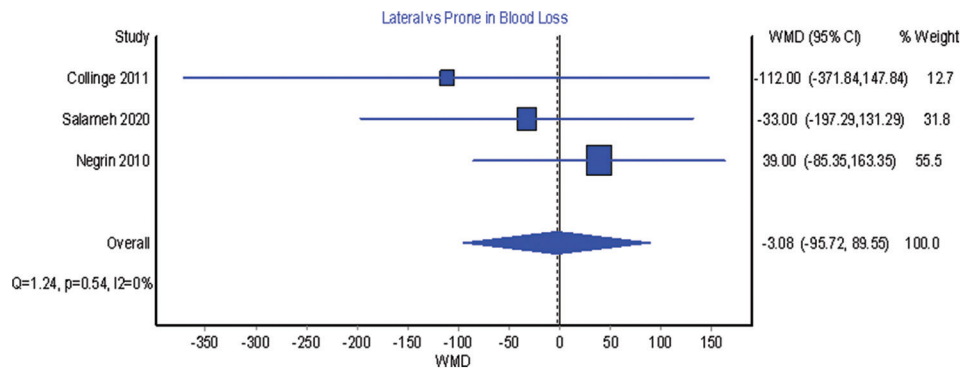
Supplementary Figure 2: Rate of matta anatomic, imperfect, and poor reduction in lateral position.



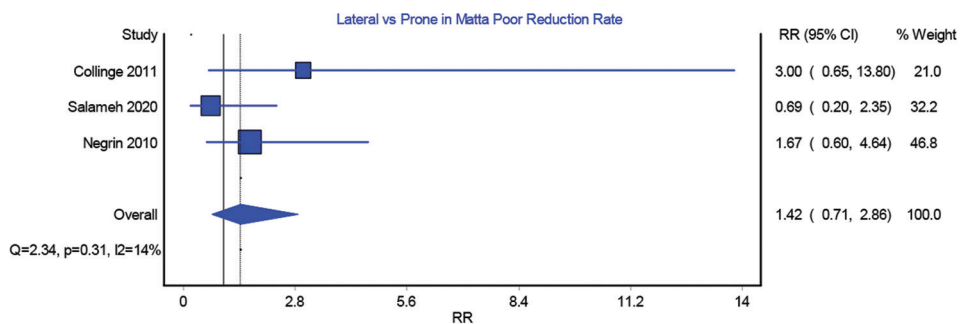
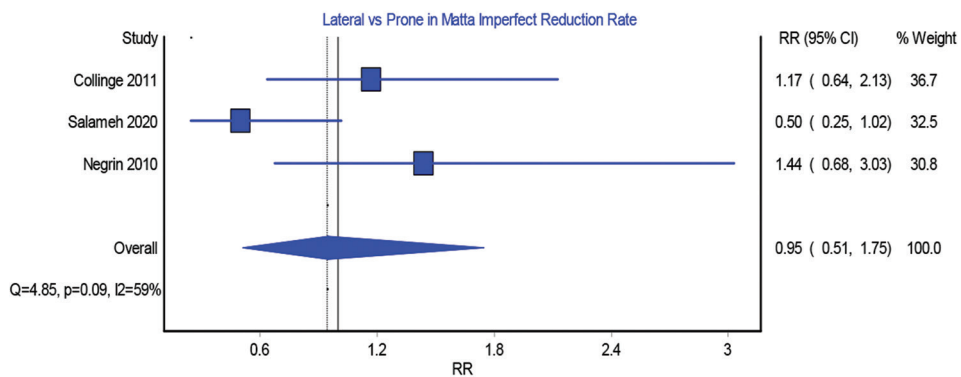
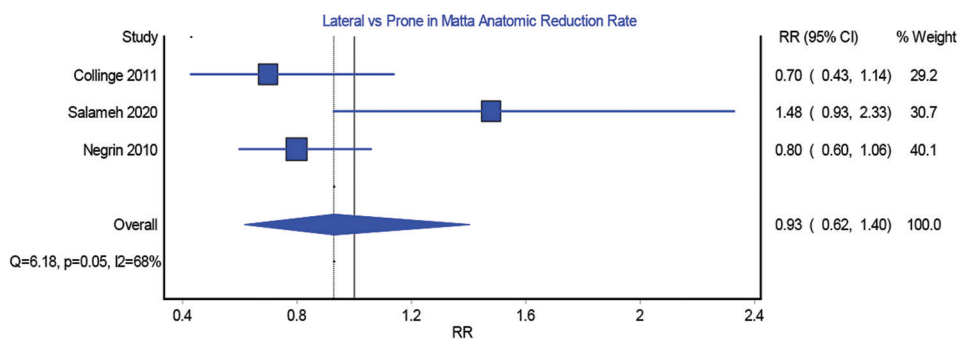
Supplementary Figure 3: Prone position intraoperative blood loss.



Supplementary Figure 4: Rate of matta anatomic, imperfect, and poor reduction in the prone position.



**Supplementary Figure 5:** Comparison between lateral and prone in intraoperative blood loss (weighted mean difference = lateral-prone).



**Supplementary Figure 6:** Comparison between lateral and prone in the rate of matta anatomic, imperfect, and poor reduction.